

Menetrier's Disease presenting with Ulcerative Colitis: A Case Report and Review of the Literature

Aref Rahimi¹, Naser Ebrahimi Daryani², Sanam Javid Anbardan³, Afshin Abdirad⁴, Zahra Azizi⁵

¹ Ardabil University of Medical Sciences, Ardabil, Iran

² Department of Internal Medicine, Division of Gastroenterology, Imam Khomeini Hospital, Tehran University of Medical Sciences, Tehran, Iran

³ Tehran University of Medical Sciences, Tehran, Iran

⁴ Imam Khomeini Hospital, Tehran University of Medical Sciences, Tehran, Iran

⁵ Iran University of Medical Sciences, Tehran, Iran

ABSTRACT

Menetrier's disease or hypertrophic gastritis is a premalignant rare disease that often presents with hypertrophy in the gastric folds, hypoalbuminemia and decreased acid secretion. There are a few papers worldwide that report concomitant Menetrier's disease and ulcerative colitis (U.C), however none are from Iran. This is the first case reported in Iranian literature. The pathogenesis of this coexistence is unknown.

We report the case of a 28-year-old woman with intermittent bilateral edema of the lower extremities, weight loss and epigastric pain associated with chronic intermittent diarrhea and one episode of nocturnal dysentery. Paraclinical evaluations showed hypoalbuminemia, low serum protein level, severe 25 OH vitamin D deficiency, a positive *Helicobacter pylori* urea breath test and negative *cytomegalovirus* (CMV) IgM antibody. Histologic, radiologic and endoscopic findings were consistent with Menetrier's disease associated with U.C. The patient was prescribed mesalazine, asacol suppositories and pantoprazole.

During a follow up visit the patient noted improvement in her symptoms. She was referred to a surgeon to discuss additional possible therapeutic treatments.

Keywords: Hypertrophic gastritis; Ulcerative colitis; Edema; Hypoalbuminemia; Vitamin D deficiency

please cite this paper as:

Rahimi A, Ebrahimi Daryani N, Javid Anbardan S, Abdirad A, Azizi Z. Menetrier's Disease presenting with Ulcerative Colitis: A Case Report and Review of the Literature. *Govaresh* 2013;18:191-6.

Corresponding author:

Zahra Azizi, MD

Iran University of Medical Sciences Tehran, Iran

Tel: + 98 21 88799446

Fax: + 98 21 88799840

E-mail: Z.Azizi.MD@gmail.com

Received: 02 Jul. 2013

Edited: 06 Aug. 2013

Accepted: 07 Aug. 2013

INTRODUCTION

Menetrier's disease, also known as giant hypertrophic gastritis and hypoproteinemic hypertrophic gastropathy was first described in 1888. This disease is considered to be a premalignant, rare disease that usually presents with hypertrophy in the gastric folds, hypoalbuminemia, decreased acid secretion, peripheral edema due to protein loss, nausea, vomiting, abdominal pain, diarrhea, asthenia, weight loss, anemia and often hypochlorhydria. The serum gastrin level is approximately normal. The average age at the time of disease presentation is around

age 55, but ranges from ages 30-60 and it is more common in men(1-6).

Proliferation of the gastric glands, cystic dilation and foveolar hyperplasia of the stomach are histopathological changes of this disease(1-5).

Some pathophysiologic changes have been attributed to this disease, such as expansion of surface mucous cells, reductions in the number of acid producing parietal cells, pepsinogen producing chief cells and attenuation of gastric acidity(2). Over expression of transforming growth factor alpha (TGF alpha) may have a role in disease pathogenesis since cetuximab, an immunoglobulin G1 monoclonal antibody (IgG1) which inhibits binding of TGF alpha to its receptor has been recently used for treating these patients(2-4, 6-9). Additionally, allergy and infections have been suggested to play a role in disease etiology(1).

While the association of Menetrier's disease with U.C. has been reported in a few cases, its etiology is unknown(3,7,10-14).

Here, we have reported the case of a 28-year-old woman with intermittent bilateral lower extremity edema due to Menetrier's disease in coexistence with U.C. This is the first case reported in Iranian literature.

CASE REPORT

A 28-year-old woman presented August 19, 2013 with intermittent bilateral lower extremity edema in her ankles, feet and occasionally legs since the last trimester of her pregnancy (1.5 years previous). The edema had been constant for the previous two months. During the last month of her pregnancy she experienced bile vomiting.

The patient had a history of weakness, fatigue, anorexia, weight loss of seven kilograms in six months, epigastric pain, tenesmus and chronic intermittent low frequency mucoid loose stools that had changed to frequent watery diarrhea since two months prior. Additionally, she experienced nocturnal dysentery with severe abdominal pain and emergency about one month before her visit. The patient claimed that all episodes of diarrhea and vomiting occurred around 3:00 am. Her medication history included pantoprazole, colofac (mebeverine), domperidone (bid), sucralfate, and a multivitamin that were prescribed for her illness prior to this clinic visit. She had a several month history of oral contraceptive pill (ocp) use. The patient denied any history of rectorrhagia, fever, sweating, arthralgia, skin and mouth lesions. Blood biochemistries were remarkable for hypocalcemia (Ca: 7.4 mg/dl), hypoalbuminemia (2.3 g/dl) and low serum protein

(4 g/dl). She had severe 25 OH vitamin D deficiency (6 ng/ml, Table 1). Urea breath test for *Helicobacter pylori* was positive and *cytomegalovirus* (CMV) IgM antibody was negative. Esophagogastroduodenoscopy (Figure 1) showed severe, enlarged gastric mucosal folds. Gastric mucosal biopsy was compatible with Menetrier's disease. A biopsy section showed gastric mucosa composed of cystically dilated glands, subtle inflammation and features consistent with hyperplastic foveolar epithelium arranged in a disorderly fashion and loss of oxyntic mucosa (Figure 2). There was no dysplasia or intestinal metaplasia observed. Colonoscopy confirmed U.C with mild colitis in the rectum and distal part of the sigmoid. There was moderate colitis in the proximal part of the sigmoid and descending colon (Figure 3). A biopsy section showed colon mucosa with accumulation of mixed inflammatory cells in the lamina propria as well as cryptitis and exceptional crypt abscess formation. Branching and budding of the glands were significant. All procedures and biopsies were performed twice by two different specialists for confirmation of Menetrier's disease and U.C. An abdominal CT scan showed diffuse gastric mucosal thickening with predominance in the body, which favored a diagnosis of Menetrier's disease rather than Crohn's disease or lymphoma. Irregular enhancing mucosa of the colon with ulceration marked in the rectum and cecum favored U.C. Other abdominal findings were normal (Figures 4 and 5). An angiography of the abdominal aorta and its branches was normal. In total, findings were consistent with Menetrier's disease associated with U.C. The patient was prescribed mesalazine (3 g qd) and asacol suppositories (bid) for her active U.C. Pantoprazole was initiated (1 per day) to reduce her upper gastrointestinal symptoms. *Helicobacter pylori* infection was treated with amoxicillin (500mg, 2 per 12 hours), clarithromycin (500mg, 1 per 12 hours) and pantoprazole (1 per 12 hours) for a two week period. At the follow up visit, the patient mentioned significant improvement in her symptoms. She was referred to a surgeon to discuss additional therapeutic management

DISCUSSION

Menetrier's disease is an infrequent entity which usually presents with hypertrophy of the gastric folds, hypoalbuminemia and a decline in acid secretion. This disease has numerous diagnostic criteria. Involvement of the fundus and body of the stomach that is associated with sparing of the antrum is a characteristic indication of Menetrier's disease(7,15). Proliferation of the gastric

Table 1: Paraclinical data.

CBC diff	Biochemistry	Hormone	Immunity markers	UA	SE
WBC: 8.60	Urea: 18	25-OH-Vit D: 6	IgA: 124	WBC: 3-4	WBC: 4-5
RBC: 5.17	Cr: 0.7	TSH: 5	Anti-tissue transglutaminase Ab (IgA): 7.4 negative	RBC: 1-2	RBC: Not seen
HB:13.4	ALK-p: 110		Anti-endomesial Ab: 8.1 negative	Epithelial cells: 20-22	Undigested food: Few
HCT: 42.2	Albumin: 2.3			Bacteria: Few	protozoa cyst : Entamoeba coli
MCV: 81.6	Ca: 7.4			Mucus: Moderate	Occult blood: negative
MCH: 25.9	P: 3.3				
MCHC: 31.8	Protein: 4				
PLT: 375000					

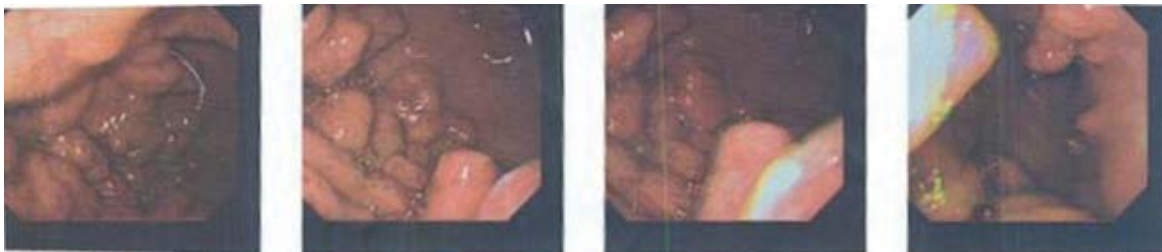


Fig. 1: Esophagogastroduodenoscopy showed enlarged gastric mucosal folds.

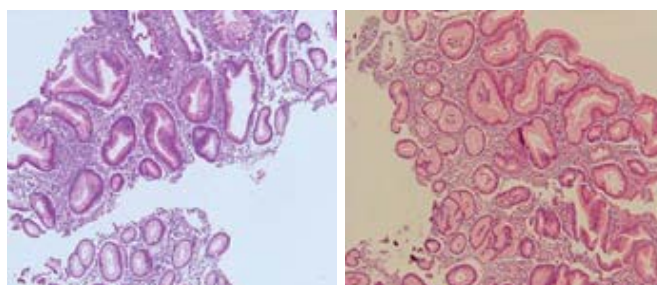


Fig. 2: Gastric mucosal biopsy. Features consist of hyperplastic foveolar epithelium arranged in a disorderly fashion with loss of oxyntic mucosa

glands, mucosal edema, cystic dilation and enlargement of gastric folds, along with tortuous foveola, foveolar hyperplasia, decrease in oxyntic glands, and loss of parietal cells are known as histological changes of this disease. There may be increased numbers of lymphocytes, eosinophils and plasma cells in the lamina propria(1-5).

Although Menetrier's disease commonly occurs in adults, some cases have been reported in infants(1). The disease in children usually occurs suddenly with spontaneous regression and is known to be related to CMV infection(4,6).

Until recently no definite treatment has been identified.

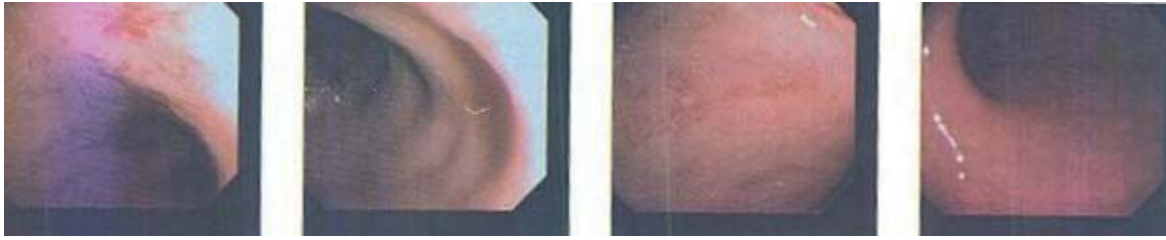


Fig. 3: Colonoscopy showed mild to moderate colitis.

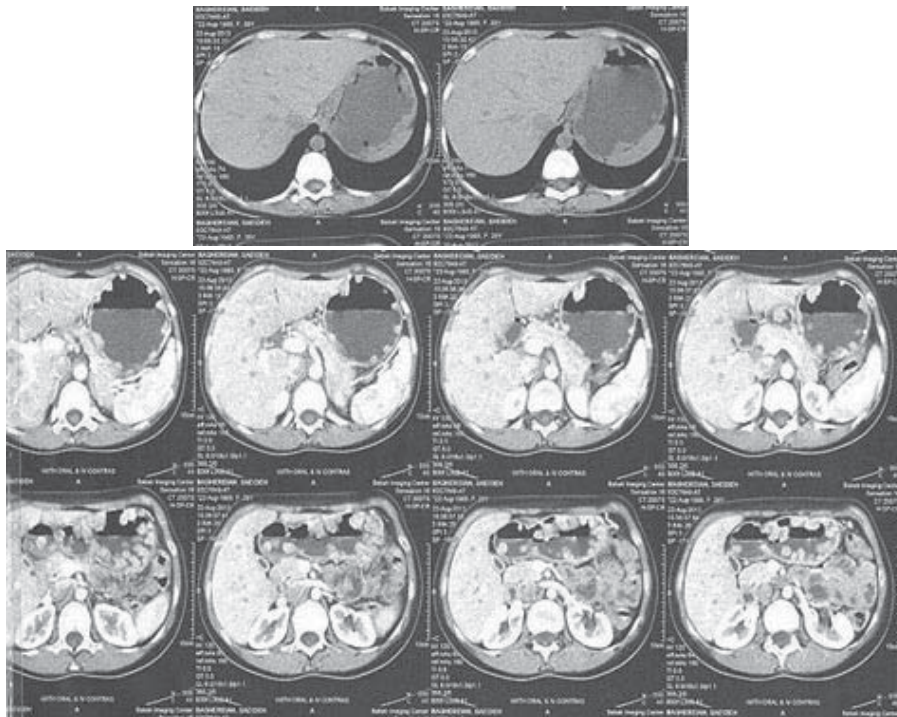


Fig. 4,5: Spiral CT scan of the abdomen & pelvis with intravenous & oral contrast.

Patients frequently underwent gastrectomies due to severe hemorrhage or edema because of hypoproteinemia(2,16). Currently medications that include octreotides, proton pump inhibitors, prednisone, antibiotics, non-steroidal anti-inflammatory drugs, anti-cholinergic agents, cetuximab and medications that eradicate *Helicobacter pylori* are used to treat Menetrier's disease. However none are definitely efficient(3-4,7-8,10,17).

Studies have shown the promising effects of somatostatin and octreotide in modulation of epidermal growth factor receptor (EGFR), hence these medications have been used to treat Menetrier's disease. Di Nardo et al(6) have reported a pediatric case that was successfully treated with long-acting release octreotide (octreotide LAR).

Additionally, allergy and infection have been

suggested to play roles in the etiology of this disease(1). Based on epidemiological evidence a strong relationship has been demonstrated between CMV(2,4,6,8), *Helicobacter pylori*(3-4,8,10) *Herpes simplex virus* and *Mycoplasma pneumonia*(9) infections in Menetrier's disease. Despite such evidence, Sweeney and Lynch(17) have reported a case with an unusual localization in the gastric antrum with no *Helicobacter pylori* infection and normal serum albumin level on first presentation. Son et al.(9) have reported a case of CMV-negative Menetrier's disease with eosinophilia in a child who improved with conservative treatment from the seventh day of hospitalization and resolved completely.

According to evidence, eradication of *Helicobacter pylori* infection and treatment of CMV infection can

result in remission of the disease. Thus it is recommended to treat patients infected with *Helicobacter pylori* who have tested positive for CMV(4,6).

In the current case, this patient had a positive *Helicobacter pylori* urea breathing test, but the CMV IgM antibody was negative. The *Helicobacter pylori* infection was eradicated with the combined use of amoxicillin, clarithromycin and pantoprazole.

Different types of polyps and polyposis syndromes, in particular juvenile polyposis syndrome can be mistaken for Menetrier's disease. Other differential diagnoses for thickening of the gastric wall include lymphoma, gastric cancer, gastrointestinal stromal tumors(GIST), tuberculosis or other infiltrative disease(4,18) A rare presentation of Menetrier's disease is gastroduodenal intussusceptions which have been reported in a few reports(5).

Hereditary and familial relationship in this disease have also been reported(1,4). The current case did not have any similar gastrointestinal diseases in her first degree family members and close relatives.

Worldwide, a few reports have discussed concomitant Menetrier's disease and U.C, however no case was from Iran(3,7,10-14). Most cases were reported after the diagnosis of U.C or when it was in remission. In very rare cases these diseases were diagnosed simultaneously. In the current patient the symptoms of Menetrier's disease and U.C were concurrent hence both diseases were diagnosed simultaneously. The pathogenesis of this coexistence is unknown however evidence has

suggested that treatment of U.C might be effective in regression of Menetrier's disease(3). For this reason, we initially focused on treatment of U.C in this patient with the intent to induce remission for both diseases.

Although Menetrier's disease is infrequent, U.C is relatively common(10). Therefore it is important to determine the etiology of an association between Menetrier's disease and U.C because if a definite connection is discovered, it is not inconceivable to expect Menetrier's disease to be more frequent in the U.C population.

In addition the serum level of 25 OH vitamin D of our patient was 6 ng/ml, which was severely deficient. This is a common phenomenon in many countries, particularly Iran. Vitamin D participates in many biological mechanisms responsible for adjusting immune responses. Evidence exists that shows the association of vitamin D deficiency with several diseases including malignancies, cardiovascular diseases, immunological dysfunctions and autoimmune diseases(19).

Therefore we propose that a probable relation between vitamin D deficiency and Menetrier's disease may exist. Further studies are necessary to determine the presence of any possible association between vitamin D deficiency and Menetrier's disease.

ACKNOWLEDGMENT

This work is supported in part by the Nutrition Research Center and Gastrointestinal and Liver Disease Research Center.

REFERENCES

- Larsen B, Tarp U, Kristensen E. Familial giant hypertrophic gastritis (Menetrier's disease). *Gut* 1987;28:1517-21.
- Coffey Jr RJ, Tanksley J. Pierre Ménétrier and His Disease. *Trans Am Clin Climatol Assoc* 2012;123:126-33; discussion 133-4.
- Hatemi I, Caglar E, Atasoy D, Goksel S, Dobrucali A. Menetrier's disease coexisting with ulcerative colitis and sclerosing cholangitis. *Dig Liver Dis* 2008;40:78-9.
- Rich A, Toro TZ, Tanksley J, Fiske WH, Lind CD, Ayers GD, et al. Distinguishing Ménétrier's disease from its mimics. *Gut* 2010;59:1617-24.
- Hayatbakhsh Abbasi MM, Darvish-Moqaddam S, Javadi A, Safavi M. A Rare Presentation of Ménétrier's Disease as Gastroduodenal Intussusception. *Middle East J Dig Dis* 2013;5:52-5.
- Di Nardo G, Oliva S, Aloï M, Ferrari F, Frediani S, Marcheggiano A, et al. A pediatric non-protein losing Menetrier's disease successfully treated with octreotide long acting release. *World J Gastroenterol* 2012;18:2727-9.
- Nguyen VX, Nguyen CC, Leighton JA, Pasha SF, Silva AC, Heppell JP, et al. The Association of Menetrier Disease with Ulcerative Colitis: A Case Report with Implications on the Pathogenesis of Menetrier Disease. *Case Rep Gastroenterol* 2010;4:66-70.
- Burdick JS, Chung E, Tanner G, Sun M, Paciga JE, Cheng JQ, et al. Treatment of Menetrier's disease with a monoclonal antibody against the epidermal growth factor receptor. *N Engl J Med*

- 2000;343:1697-701.
9. Son KH, Kwak JJ, Park JO. A case of cytomegalovirus-negative Ménétrier's disease with eosinophilia in a child. *Korean J Pediatr* 2012;55:293-6.
 10. Hemmings CT. Menetrier's disease in a patient with ulcerative colitis: a case report and review of the literature. *Pathology* 2007;39:282-3.
 11. Ojeda E, Ruiz J, Cosme A, Lobo C. Menetrier disease associated with ulcerative colitis. Response to the treatment with octreotide. Review of the diagnostic criteria and etiopathogenesis. *Gastroenterol Hepatol* 1997; 20:175-9.
 12. Belhocine K, Chaoui F. [Menetrier disease and ulcerative colitis--an unusual association]. *Gastroenterol Clin Biol* 2006;30:1105-7.
 13. Mirkovic D, Doder R, Ilic S, Mitrovic M, Ignjatovic M. [Menetrier's disease associated with ulcerative colitis]. *Vojnosanit Pregl* 2003;60:747-51.
 14. Sasaki E, Toyonaga A, Murayama S, Kuboyama S, Sasaki S, Inuzuka S, et al. [A case report of Menetrier's disease developed in a patient with ulcerative colitis]. *Nihon Shokakibyō Gakkai Zasshi* 1991;88:96-9.
 15. Coffey RJ, Washington MK, Corless CL, Heinrich MC. Menetrier disease and gastrointestinal stromal tumors: hyperproliferative disorders of the stomach. *J Clin Invest* 2007;117:70-80.
 16. Jarnum S, Jensen KB. Plasma protein turnover (albumin, transferrin, IgG, IgM) in Ménétrier's disease (giant hypertrophic gastritis): Evidence of non-selective protein loss. *Gut* 1972;13:128-37.
 17. Sweeney AR, Lynch MK. A case of Menetrier's disease localized to the gastric antrum without helicobacter infection or hypoalbuminemia. *Int J Surg Case Rep* 2013;4:839-41.
 18. Ungaro R, Babyatsky MW, Zhu H, Freed JS. Protein-losing enteropathy in ulcerative colitis. *Case Rep Gastroenterol* 2012;6:177-82.
 19. Yang C-Y, Leung PS, Adamopoulos IE, Gershwin ME. The implication of vitamin D and autoimmunity: a comprehensive review. *Clin Rev Allergy Immunol* 2013;45:217-26.