

Dropped Gallstones during Laparoscopic Cholecystectomy

Azam Teimuri¹, Masood Mami², Hadi Ghofrani³, Naser Ebrahimi Daryani⁴, Asghar Khosravi²,
Forough Alborzi²

¹ Assistant Professor of Isfahan University of Medical Sciences, Isfahan, Iran.

² Fellow of Gastroenterology, Department of Gastroenterology and Hepatology, Imam Khomeini Hospital, Tehran University of Medical Sciences, Tehran, Iran.

³ Associate Professor, Department of Gastroenterology and Hepatology, Imam Khomeini Hospital, Tehran University of Medical Sciences, Tehran, Iran.

⁴ Professor, Department of Gastroenterology and Hepatology, Imam Khomeini Hospital, Tehran University of Medical Sciences, Tehran, Iran

ABSTRACT

Laparoscopic cholecystectomy (LC) is one of the most commonly performed surgeries worldwide. Stones can be spilled from the gallbladder during LC. These stones can be left in the peritoneal cavity or trapped at the trocar site. The potential late sequelae and associated morbidity are not well documented. Every effort should be made in order to avoid spillage of stones during dissection of the gallbladder through the abdominal wall. We describe one case that underwent LC and presented with dropped gallstones.

Keywords: Laparoscopy; Cholecystectomy; Dropped; Gallstone

please cite this paper as:

Teimuri A, Mami M, Ghofrani H, Ebrahimi Daryani N. Dropped Gallstones during Laparoscopic Cholecystectomy. *Govaresh* 2014;19:66-8.

INTRODUCTION

Laparoscopic cholecystectomy (LC) is an increasingly popular procedure in the treatment of patients with symptomatic gallstones. Although LC offers wide a range of advantages (less invasive, faster discharge) it results in some uncommon and characteristic complications. The most common of these are bile duct injury, gallbladder perforation, liver

laceration, pneumomediastinum, pneumothorax, and intraperitoneal abscess. Gallbladder perforation and intraperitoneal gallstone spillage have been estimated to occur in up to one-third of patients undergoing LC. Fortunately clinically significant complications from intraperitoneal gallstones are extremely uncommon.

CASE REPORT

A 77-year-old man presented to his gastroenterologist with a three month history of abdominal discomfort in the right upper quadrant on deep breathing and dry cough. His past medical history was remarkable for diabetes mellitus, hypertension, ischemic heart disease and history of LC performed three months prior for treatment of acute cholecystitis with multiple stones in the gallbladder.

A CT scan of the abdomen revealed multiple high density stones associated with reactive and inflammatory changes in the subphrenic spaces without any abscess formation (Figure 1). The CT scan of the

Corresponding author:

Naser Ebrahimi Daryani, MD
Second Floor, No. 130, Shahid Naseri Street,
Valiasr Ave., Tehran, Iran

Tel: + 98 21 88793896

Fax: + 98 21 88799840

E-mail: nebrahim@sina.tums.ac.ir

Received: 05 Feb. 2014

Edited: 28 Mar. 2014

Accepted: 29 Mar. 2014

thorax demonstrated right sided pleural thickening and pleural effusion however there were no abscesses or consolidation visualized.

He was treated with appropriate antibiotics and anti-inflammatory drugs. At the one month follow up visit, his thorax and abdominal CT scans were repeated. The patient was symptom-free and in comparison with the prior CT scan, there was resolution of the right-sided pleural effusion. Therefore the patient was recommended for close observation and follow up. We referred the patient to his surgeon for either observation or under certain conditions, laparoscopic removal of the gallstones.

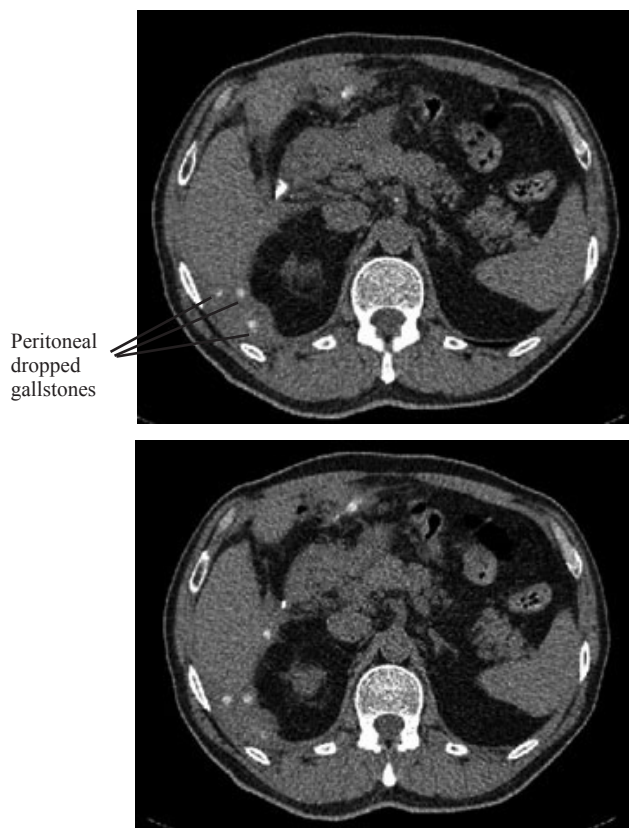


Fig. 1: Post laparoscopic abdominal CT scan of the patient. Some stones were seen in the peritoneum near the liver.

DISCUSSION

In the United States, more than 700,000 LCs are performed each year and the number is growing(1). Since 1985 LC has become the gold standard for treatment of symptomatic gallstone disease(2). The benefits of LC for gallbladder surgery are significant; it minimizes mortality rates in the perioperative period,

reduces the length of hospital stay and allows patients to return to their normal activities sooner compared to open cholecystectomy(2). However LC carries some major complications including damage to the biliary system, blood vessels, and gastrointestinal tract(2). As many as one third of all LCs are complicated by dropped gallstones(1,3-5). Gallstones may also be dropped during open cholecystectomy, but the larger operating field makes them easier to retrieve(1). Most patients with dropped gallstones remain asymptomatic(6). The majority of surgeons believe that free intraperitoneal gallstones are harmless and do not agree with performing a laparotomy, even when large numbers of gallstones are left in situ(5). Nevertheless, recognition of this unusual entity is important because the clinical presentation can be confusing, thus delaying the diagnosis(7). Early diagnosis is the key to avoid long and unnecessary treatment(1). If dropped gallstones become infected and eventually cause symptoms, they may require surgical or percutaneous removal in conjunction with antimicrobial therapy(1). Dropped stones produce an intra-abdominal abscess in 0.6%-2.9% of dropped stones cases and bile spillage based on reports by Rice et al. and Morrin et al.(14,15) Abscess formation has been reported to happen as early as four days and as late as ten years after LC(7).

It remains controversial whether stone spillage should be considered an indication for an open cholecystectomy(7). Soper and Dunnegan (5,8) and Schafer et al.(5,9) have analyzed 10174 LCs performed at 82 surgical institutions over a three-year period. These researchers advised surgeons against converting LC to an open procedure. Their findings showed that the mortality rate and the incidence of serious complications of retained gallstones were extremely low(5). Welch et al. and Cohen et al. have concluded that free intraperitoneal gallstones are harmless and therefore do not warrant the performance of an exploratory laparotomy(5,10,11). Leland and Dawson, and Tzardis et al. have suggested that intraperitoneal stones could lead to an even higher incidence of adhesion formation and abscess formation, and therefore they concluded that unretrieved gallstones were not benign and should be aggressively removed in order to decrease long term complications(5,7,12,13). In a study by Tumer et al., two patients who suffered from complications related to dropped stones were successfully managed medically(5). Our case had a few symptoms including abdominal discomfort and dry cough that successfully resolved after medical management. As with the cases of Tumer et al., we decided to limit our management to

medical treatment and close observation.

A negative outcome such as gallstone spillage is not evidence of malpractice. Negligence cannot be imputed from unsatisfactory results. The prudent surgeon should inform the patient preoperatively about the possibility of gallstone spillage. When gallbladder perforation and gallstone spillage occur during LC, an effort should be made to retrieve the gallstones by using a variety of extraction instruments such as grasping forceps, a Dormia basket, and a 10 mm irrigation and suction device, among others; the peritoneum should be irrigated with saline. There is no indication, however, for converting the laparoscopic procedure to

a laparotomy purely on the basis of spilled stones, but it is essential to document spilled stones in the operative notes.

The surgeon should inform the patient post-operatively of the event and the possibility of abscess formation and additional complications. Such patients should be kept under close observation to avoid spending time and money on unnecessary examinations, as well as the psychological trauma associated with a wrong diagnosis such as malignancy.

REFERENCES

1. Mahmood SK, Tomford J.W, Rosenblatt S, Gordon. The clinical picture dropped gallstones distinguished as a liver abscess. *Cleve Clin J Med* 2008;75:316-8.
2. Kuldeep S, Ming L.W, Emmanuel O, Aziz A, Miles N. Gallstone abscess as a result of dropped gallstones during laparoscopic cholecystectomy. *Int J Surg Case Rep* 2012; 3:611-3.
3. Lohan D, Walsh S, McLoughlin R, Murphy J. Imaging of the complications of laparoscopic cholecystectomy. *Eur Radiol* 2005;15:904-12.
4. Casillas S, Kittur DS. Late abscess formation after spilled gallstones masquerading as a liver mass. *Surg Endosc* 2003;17:833.
5. Tumer AR, Yuksek YN, Yasti AC, Gozalan U, Kama NA. Dropped gallstones during laparoscopic cholecystectomy: the consequences. *World J Surg* 2005;29:437-40.
6. Shum JSF, Fung KH, Yang GPC, Tang CN, Li MKW. Combined percutaneous and endoscopic approach in management of dropped gallstones following laparoscopic cholecystectomy. *J Radiol Case Rep* 2010;41:1-5.
7. Roberts DJ, Chun HM. Dropped gallstones as a nidus intra-abdominal abscess complicated by empyema. *Clin Infect Dis* 2005;41:e64-6.
8. Soper NJ, Dunnegan DL. Does intra operative gallbladder perforation influence the early outcome of laparoscopic cholecystectomy? *Surg Laparosc Endosc* 1991;1:156-61.
9. Schäfer M, Suter C, Klaiber C, Wehrli H, Frei E, Krähenbühl L. Spilled gallstones after laparoscopic cholecystectomy: a relevant problem? A retrospective analysis of 10,174 laparoscopic cholecystectomies. *Surg Endosc* 1998;12:305-9.
10. Welch N, Hinder RA, Fitzgibbons RJ Jr, Rouse JW. Gallstones in the peritoneal cavity: a clinical and experimental study. *Surg Laparosc Endosc* 1991;1:246-7.
11. Cohen RV, Pereira PR, de Barros MV, Ferreira EA, de Tolosa EM. Is the retrieval of lost peritoneal gallstones worthwhile? *Surg Endosc* 1994;8:1360.
12. Leland DG, Dawson DL. Adhesion and experimental intraperitoneal gallstones. *Contemp Surg* 1993; 42:273-6.
13. Tzardis PJ, Vougiouklakis D, Lymperi M, Kritikos E, Paraschou E, Tierris E, et al. Septic and other complications resulting from biliary stones placed in the abdominal cavity: experimental study in rabbits. *Surg Endosc* 1996;10:533-6.
14. Morrin MM, Kruskal JB, Hochman MG, Saldinger PF, Kane RA. Radiologic features of complications arising from dropped gallstones in laparoscopic cholecystectomy patients. *AJR Am J Roentgenol* 2000; 179: 1441-1445.
15. Rice DC, Memon MA, Jamison RL, et al. Long term consequences of intraoperative spillage of bile and gallstones during laparoscopic cholecystectomy. *J Gastrointest Surg* 1997; 1:85-91.