

Allergic Eosinophilic Gastroenteritis with Rectorrhagia

Mandana Rafeey¹, Mahnaz Sadeghi-Shabestari², Amir Eftekhar Sadat³,
Robabeh Ghergherehchi⁴

Case Report

¹Professor, Head of Pediatric Gastroenterology & Hepatology & Nutrition Ward, Liver & Gastrointestinal Research Center, Tabriz University of Medical Sciences, Tabriz, Iran

²Associated Professor of Clinical Immunology and Allergy, TB and Lung Research Center of Tabriz, Tabriz University of Medical Sciences, Tabriz, Iran

³Consultant Pathologist, Emam Reza Hospital, Tabriz University of Medical Sciences, Tabriz, Iran

⁴Associated Professor of Endocrinology, Tabriz University of Medical Sciences, Tabriz, Iran

ABSTRACT

Eosinophilic gastroenteritis (EGE) was a rare gastrointestinal disease that was seen in all ages usually associated with dyspepsia, diarrhea, vomiting, abdominal pain, blood loss in stools and malabsorption.

We reported a six-month-old boy with rectorrhagia, family history of allergy, elevated IgE and eosinophil in blood with normal endoscopy. Because of eosinophilic infiltration in lamina propria in colon, diagnosis of EGE confirmed and oral corticosteroid initiated. Patient had symptomatic response and was doing well.

The heterogeneity in the clinical presentation of EGE determined by the site and depth of eosinophilic intestinal infiltration and lower gastrointestinal bleeding, although was rare but may be one of the clinical manifestations of disease in patients with allergic eosinophilic gastroenteritis (AEG).

Keywords: Eosinophilic gastroenteritis; Lower gastrointestinal bleeding; Allergy; Infant

please cite this paper as:

Rafeey M, Sadeghi-Shabestari M, Eftekhar Sadat A, Ghergherehchi R. Allergic Eosinophilic Gastroenteritis with Rectorrhagia. *Govaresh* 2014;19:146-8.

INTRODUCTION

Laparoscopic cholecystectomy (LC) is an increasingly popular procedure in the treatment of patients with symptomatic gallstones. Although LC offers wide a range of advantages (less invasive,

faster discharge) it results in some uncommon and characteristic complications. The most common of these are bile duct injury, gallbladder perforation, liver laceration, pneumomediastinum, pneumothorax, and intraperitoneal abscess. Gallbladder perforation and intraperitoneal gallstone spillage have been estimated to occur in up to one-third of patients undergoing LC. Fortunately clinically significant complications from intraperitoneal gallstones are extremely uncommon. Eosinophilic gastroenteritis is characterized by multiple GI symptoms, Eosinophilic infiltration in one or more areas of the GI tract, 20 or more eosinophils per high-power field, absence of an identified cause of eosinophilia and exclusion of eosinophilic involvement in organs other than the GI tract. A history of atopic or food allergies was present

Corresponding author:

Mahnaz Sadeghi-Shabestari, MD

Clinical Immunology and Allergy, TB and Lung
Research Center of Tabriz, Tabriz University of
Medical Sciences, Tabriz, Iran

Telefax: + 98 411 5262250

E-mail: drsadeghim2004@yahoo.com

Received: 18 Mar. 2014

Edited: 25 May 2014

Accepted: 26 May 2014

more than 40% of cases.

Although EGE was originally described in 1937 by Kaijser, more than 280 cases have been reported in medical literature to now(1). Even though these illnesses were idiopathic, current survey showed the role of eosinophils, T helper 2 (Th2) cytokines as the important factors in the contributory role pathogenesis of eosinophilic gastroenteritis(2). This article presented a case of chronic bloody diarrhea diagnosed as EGE. The initial step in detecting was suspecting EGE so; it should be mention in every patient with persistent bloody diarrhea.

CASE REPORT

A six month old boy with diagnose of amoebic colitis disease without response to treatment, was admitted in hospital. In the past he had a history of abdominal distension, vague pain and loose bloody stools for one month and family history of allergy.

Laboratory data reveals hypo proteinemia (Pro total=5/6mg/dl, Alb=2/9 mg/dl), anemia(HB=9/2 g/dl), a WBC count of 13.300mm³, eosinophil count of 30% (normal 0%-1%), Elevated IgE (102 IU/L), ESR=15mm/h without ova or cysts in stool examination. Abdominal Ultrasonography was normal.

In physical examination, he had itching of nose, eyes, and nasal congestion for 3 months ago and family history of Allergic Rhinitis his mother was positive. Barium meal and upper gastrointestinal endoscopy with biopsy from the duodenum was normal. For evaluating of allergy, skin prick test with common allergens performed which had positive results (wheal and erythema) for eggs, milk, oats, wheat, and peanuts. His mother began an elimination diet based on prick testing and treatment for patient initiated with exclusive breast-feeding and antihistamine (figure 1).

After few days, frequent episodes of vomiting with rectorrhagia developed. Histology of colonic biopsies showed eosinophilic infiltration in lamina proper especially at the periphery of lymphoid aggregate (figure 2) and a final diagnosis of eosinophilic enteritis made. Treatment with oral prednisolone 2mg/kg started and took for three months. He had a good response to treatment and get better with reduction in diarrhea frequency. Now he is well.

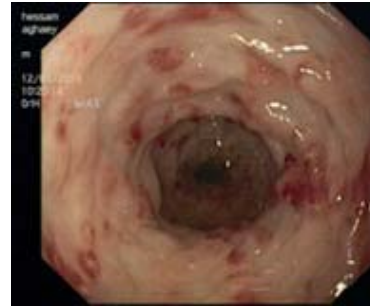

Fig. 1: Colonoscopy finding

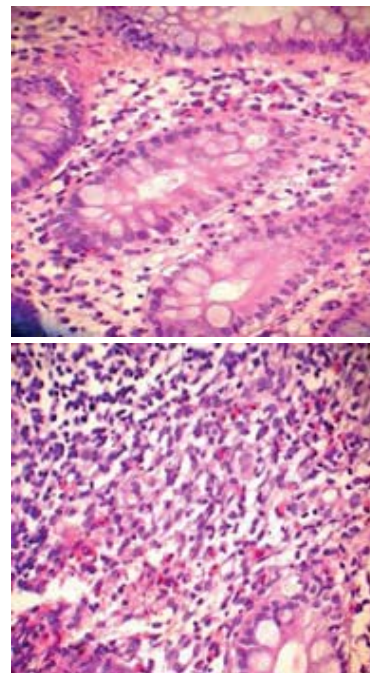


Fig. 2: Pathologic finding

DISCUSSION

Diagnosis of Eosinophilic gastroenteritis (EGE) is depends on the anatomical site and layer of gastrointestinal tract that is involved. This disorder have classified into mucosal, submucosal and subserosal disease (3-5).

The most common clinical manifestations of eosinophilic gastroenteritis are abdominal pain (90%), diarrhea (60%), vomiting (60%), nausea (50%), and abdominal distension (50%) (6,7).

A positive history of allergy in patient and eosinophilia in peripheral smear will help to early diagnosis of EGE because more than 50% of patients

have a history of atopy (e.g. hay fever, asthma, food allergy) especially in children. Allergy testing with foods and eliminating diets are recommended for patients with EGE before a trial of corticosteroids and effective in most patients, such as children. Spontaneous remission has shown in up to 40% of patients (8-10).

Corticosteroids are the main treatment for EGE with good response in most patients. Symptoms usually improve within a few weeks of treatment(11-14). Histamine H-1 receptor antagonists or mast cell-stabilizing drugs (eg, cromoglycate), may be used in patients who have not respond to corticosteroid therapy(15-17).

Our patient had nausea, bloody stool, vomiting

and clinical manifestations of allergic rhinitis with positive history of allergic rhinitis his mother, So food allergy propounded but presence of rectorrhagia with no response to antihistamines drug alone, suggested that other diagnosis such as EGE must be consider. Therefore, patient was treated with a corticosteroids and responded symptomatically and his abdominal distention, diarrhea, vomiting, rectorrhagia completely resolved.

Eosinophilic gastroenteritis is a chronic gastrointestinal disease that may present with a variety of clinical manifestations, so for early diagnosis thinking about Eosinophilic gastroenteritis in differential diagnosis was needed.

REFERENCES

- Whitaker IS, Gulati A, McDaid JO, Bugajska-Carr U, Arends MJ. Eosinophilic gastroenteritis presenting as obstructive jaundice. *Eur J Gastroenterol Hepatol* 2004;16:407-9.
- Jung Y, Rothenberg ME. Roles and Regulation of Gastrointestinal Eosinophils in Immunity and Disease. *J Immunol* 2014;193:999-1005.
- Behjati S, Zilbauer M, Heuschkel R, Phillips A, Salvestrini C, Torrente F, et al. Defining Eosinophilic Colitis in Children: Insights from a Retrospective Case Series. *J Pediatr Gastroenterol Nutr* 2009;49:208-15.
- Klein NC, Hargrove RL, Sleisenger MH, Jeffries GH. Eosinophilic gastroenteritis. *Medicine* 1970; 49:299-319.
- Aceves S, Hirano I, Furuta GT, Collins MH. Eosinophilic gastrointestinal diseases--clinically diverse and histopathologically confounding. *Semin Immunopathol* 2012 ;34:715-31.
- Kelly KJ. Eosinophilic gastroenteritis. *J Pediatr Gastroenterol Nutr* 2000; 30 Suppl:S28-S35.
- Neustrom MR, Friesen C. Treatment of eosinophilic gastroenteritis with montelukast. *J Allergy Clin Immunol* 1999;104:506.
- Walker NI, Croese J, Clouston AD, Parry M, Loukas A, Prociw P. Eosinophilic enteritis in northeastern Australia. Pathology, association with *Ancylostoma caninum*, and implications. *Am J Surg Pathol* 1995;19:328-37.
- Yan BM, Shaffer EA. Primary eosinophilic disorders of the gastrointestinal tract. *Gut* 2009;58:721- 32.
- Chehade M, Magid MS, Mofidi S, Nowak-Wegrzyn A, Sampson HA, Sicherer SH. Allergic eosinophilic gastroenteritis with protein-losing enteropathy: intestinal pathology, clinical course, and long-term follow-up. *J Pediatr Gastroenterol Nutr* 2006;42:516- 21.
- Justinich C, Katz A, Gurbindo C, Lepage G, Chad Z, Bouthillier L, et al. Elemental diet improves steroid-dependent eosinophilic gastroenteritis and reverses growth failure. *J Pediatr Gastroenterol Nutr* 1996; 23: 81- 5.
- Talley NJ, Shorter RG, Phillips SF, Zinsmeister AR. Eosinophilic gastroenteritis: a clinicopathological study of patients with disease of the mucosa, muscle layer, and subserosal tissues. *Gut* 1990;31:54-8.
- Naylor AR. Eosinophilic gastroenteritis. *Scott Med J* 1990;35:163-5.
- Lee M, Hodges WG, Huggins TL, Lee EL. Eosinophilic gastroenteritis. *South Med J* 1996;89:189-94.
- Di Gioacchino M, Pizzicannella G, Fini N, Falasca F, Antinucci R, Masci S, et al. Sodium cromoglycate in the treatment of eosinophilic gastroenteritis. *Allergy* 1990;45:161-166.
- erez-Millan A, Martin-Lorente JL, Lopez-Morante A, Yuguero L, Saez-Royuela F. Subserosal eosinophilic gastro-enteritis treated efficaciously with sodium cromoglycate. *Dig Dis Sci* 1997;42:342-4.
- Melamed I, Feanny SJ, Sherman PM, Roifman CM. Benefit of ketotifen in patients with eosinophilic gastroenteritis. *Am J Med* 1991;90:310-4.