

## Primary Hepatic Amyloidosis with Severe Cholestasis: A Case Report

Marziye Ghalamkari<sup>1</sup>, Mahdi khatuni<sup>1</sup>, Mohammad Taher<sup>2</sup>, Mahmood Khaniki<sup>3</sup>

<sup>1</sup>Researcher, Department of Internal Medicine, Imam Khomeini Hospital, Tehran University of Medical Sciences, Tehran, Iran

<sup>2</sup>Fellowship of Gastroenterology, Imam Khomeini Hospital, Tehran University of Medical Sciences, Tehran, Iran

<sup>3</sup>Assistant Professor, Department of Pathology, Imam Khomeini Hospital, Tehran University of Medical Sciences, Tehran, Iran

### ABSTRACT

Despite the fact that hepatic involvement is frequently seen in systemic primary amyloidosis, major hepatic symptoms as primary manifestation and severe impaired liver function are rare. Herein, we report a 38-year-old woman with primary hepatic amyloidosis, and severe portal hypertension. The patient had ascites and markedly elevated alkaline phosphatase level at presentation. She had a rapid downhill course resulting in death. In case of an unexplained intrahepatic cholestasis or portal hypertension the possibility of amyloidosis should be considered and a Congo red staining should be performed.

**Keywords:** Intrahepatic cholestasis, Primary amyloidosis, Liver amyloidosis

*please cite this paper as:*

Ghalamkari M, khatuni M, Taher M, Khaniki M. Primary Hepatic Amyloidosis with Severe Cholestasis: A Case Report. *Govaresh* 2016; 21: 76-80.

### INTRODUCTION

Primary amyloidosis is an uncommon disease, which is caused by extracellular deposition of insoluble polymeric protein fibrils in tissues and organs(1). The most common manifestations of primary amyloidosis are related to the deposition of amyloid fibrils in the kidney, heart, and peripheral nervous system(2).

The liver is also a common site of involvement, but this is usually mild and asymptomatic. Clinical manifestations such as cholestasis and portal hypertension as in the present case are rare(3).

#### Corresponding author:

Mohammad Taher, MD

Imam Khomeini Hospital, Tehran University of Medical Sciences, Tehran, Iran

Telefax: +98 21 61192639

E-mail: [Dr.tahermdir@gmail.com](mailto:Dr.tahermdir@gmail.com)

Received: 24 Oct. 2015

Edited: 17 Feb. 2016

Accepted: 18 Feb. 2016

Nevertheless such patients have generally poor prognosis(4). In cases of progressive hepatic failure with cholestasis especially in fulminant hepatitis, amyloidosis is an infrequent challenge among clinicians(5).

The wide range and unusual presenting symptoms of amyloidosis make rapid clinical diagnosis difficult. Unfortunately present laboratory studies and radiological techniques are not fully effective in the diagnosis. So the diagnosis depends on taking tissue biopsy, which would last more than other techniques(5).

Herein, we describe a patient with hepatic amyloidosis, which fulminant hepatitis was her primary presentation. We demonstrate more detailed involvement of liver in amyloidosis.

### CASE REPORT

A 38-year-old woman was admitted to Imam Khomeini Hospital (affiliated to Tehran University of Medical Sciences) because of one month history of vague epigastric pain and progressive jaundice. She had a history of anorexia and about 3kg weight loss

**Table 1: Laboratory data of our patient at presentation**

Variables	Our patient	Normal range
White blood cells (103/ $\mu$ L)	14.2 (polymorphonuclear: 65%)	4.5-10
Hemoglobin (gr/dL)	10.7	13-15.5
Platelet(103/ $\mu$ L)	237	150-400
Creatinine (mg/dL)	0.5	0.5 to 1.0
Calcium (mg/dL)	8.5	
ESR 1th hour (mm/h)	9	<50
LDH (U/L)	369	50-150
Serum protein(gr/dL)	6.9	
Albumin (g/dL)	2.8	3.5-5.5
Aspartate aminotransferase (U/L)	35	<31
Alanine transaminase (U/L)	191	<31
Bilirubin (mg/dL)(total, direct)	10.5, 7.4	<1.2,<0.3
Alkaline phosphatase(U/L)	1128	64-306
Gama glutamyltranspeptidase (U/L)	534	<32
International normalized ratio	1.6	1-1.4
Partial thromboplastin time (second)	15	25-40

during the recent month. She also noticed pale stool and dark urine.

The patient had normal health status until one month ago. She was single and had no history of previous diseases or medication. She had no known allergy, did not smoke, drink alcohol, or use illicit drugs. Her family history was unremarkable.

On physical examination, she was a middle aged, oriented woman. Her vital signs were normal. She did not have orthostatic hypotension. Her sclera was icteric, and the abdomen was soft and distended. The shifting dullness test was positive. In the lower extremities she had 2<sup>+</sup> symmetric pitting edema. The other examinations were normal. The patient's laboratory data has been shown in table 1.

Other laboratory findings included: urine analysis was positive for proteinuria and 24-hour urine analysis showed 1000 mg/day urinary protein excretion.

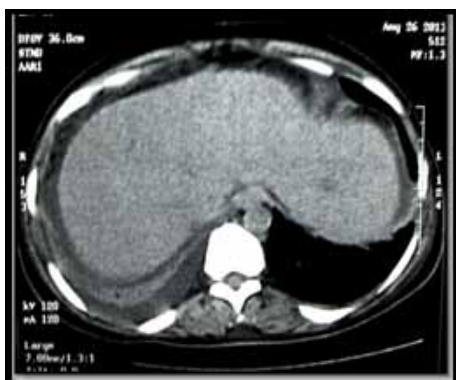Ultrasonography of the abdomen demonstrated moderate ascites and slightly coarse liver contour without dilatation of biliary ducts. Ascites fluid was tapped, which showed albumin: 0.4gr/dl, and protein: 0.8 gr/dl, which due to serum albumin (Alb: 2.8 g/dl) was high SAAG (serum ascites albumin gradient), and low protein ascites. Viral markers were negative. Also tests for autoimmune hepatitis and primary biliary cirrhosis (including anti-nuclear antibody(ANA), anti-

smooth muscle antibody(ASMA), anti-liver kidney microsomal antibody(anti LKM Ab) and anti-mitochondrial antibody(AMA) were negative. Upper gastrointestinal (GI) endoscopy was performed, which showed no esophageal varices.

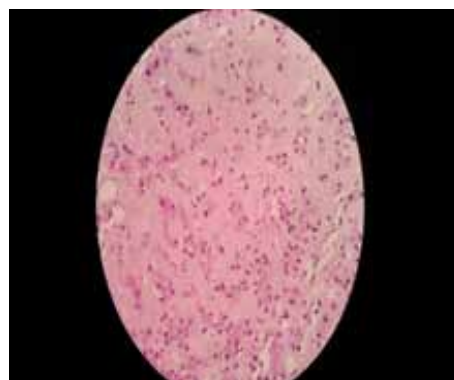During the first week of admission, she gradually developed dyspnea, her edema deteriorated, and she had PO(per oral) intolerance.

Chest computed tomography (CT) showed right sided pleural effusion and abdominal CT showed dirty mesentery and bowel wall thickening with little fatty infiltration in the liver (figure 1). MRCP(magnetic resonance cholangiopancreatography) was normal without any sign of obstruction in the biliary tract. So, liver core needle biopsy was performed. Pathological examination of the biopsy sample showed diffuse atrophy or melting of hepatocytes by marked deposition of amorphous hyalinoid substance in intrahepatocytic spaces (figure 2). Congo red stain showed positive reactivity by polarized microscopy (figures 3, and 4). Reticulin stain revealed widening of Disse spaces (figure 5: A,B). There was evidence of intrahepatic cholestasis without fibrotic reaction (figure 6) consistent with amyloidosis (beta fibrilosis) of liver.

Additional examinations were done, to evaluate the extent of organ involvement by amyloid fibrils.



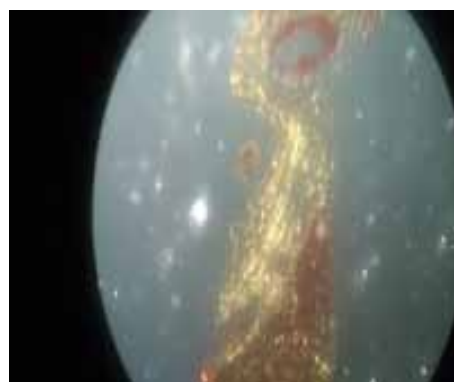**Fig. 1:** Abdominal tomogram showing little fatty infiltration in the liver with ascites.



**Fig. 2:** Atrophy of hepatocyte plates by massive eosinophilic extracellular deposition along the sinusoid Disse space. (H&E;\*400)



**Fig. 3:** Obviously amorphous deposits (amyloid) in hepatic sinusoids melting liver parenchyma (Congo red stain;\*400)



**Fig. 4:** Green birefringence confirming amyloid nature of deposits (polarized microscopy\*400)

Bone marrow aspiration/biopsy was normal. In 2D Doppler echocardiography no systolic and diastolic dysfunction was found.

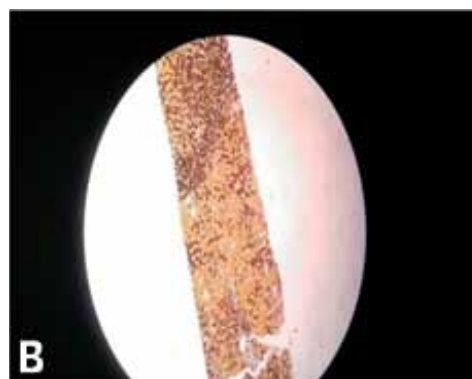
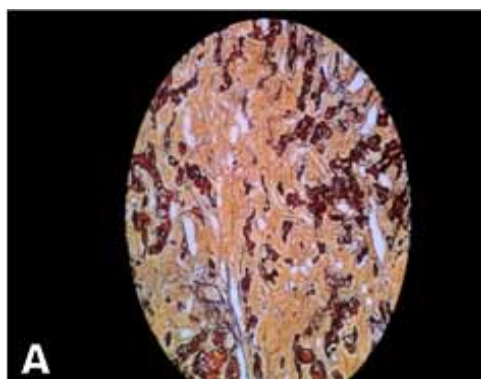
The patient was diagnosed as having hepatic amyloidosis but unfortunately before initiating chemotherapy she died due to severe hepatic failure with hepatic encephalopathy.

## DISCUSSION

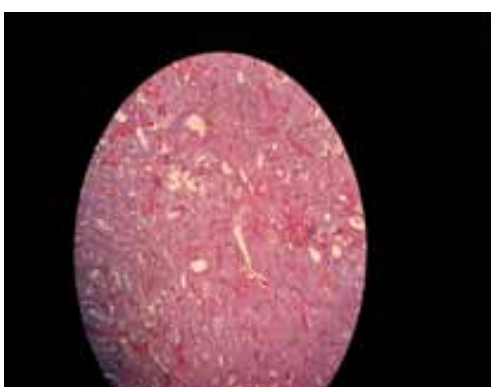Amyloid deposits can be isolated to a single organ such as GI tract. The liver is involved in approximately 60% of patients with light chain amyloidosis(AL) amyloidosis(4). But it is rarely associated with significant clinical manifestations. The most common symptoms are weight loss, fatigue, abdominal pain, and nausea. The most common physical finding is hepatomegaly (in 81% of patients with primary amyloidosis), ascites, and edema(6). In our patient as ultrasonography and CT confirmed, liver size was

normal. In laboratory investigations we can see abnormal alkaline phosphatase (usually more than 500 U/L), which was 1128 in our patient, and AST was more than twice the upper normal limit. Although hepatic involvement can be massive in patients with primary amyloidosis, clinical manifestations at presentation including cholestasis and portal hypertension, as in the present case, are rare.

In 1971, when Levy and colleagues described a patient with severe cholestatic jaundice and primary amyloidosis(3), a review of the published reports revealed other patient with similar syndrome(7-15). In 1988 Gertz and co-workers presented a series of primary amyloidosis in which hepatic involvement had led to diagnosis. Liver function test impairment was mild or absent. The most common abnormality was raised ALP or AST levels. Elevation of serum bilirubin concentration was exceedingly rare (only 8% of patients have serum bilirubin level more than 30



**Fig. 5:** Mildly disrupted reticulin meshwork of liver tissue due to the expansion of Disse space by deposits (silver stain; A:\*400.B:\*200)



**Fig. 6:** Liver tissue distortion by extracellular deposition with no evidence of fibrotic reaction (Trichrome;\*400).

$\mu\text{mol/L}$ )(4). In 1971 Levy and colleagues during a review of literature reported that the prevalence of jaundice in AL amyloidosis was less than 5%(2), although our patient's chief complaint was jaundice. Ascites has also a prevalence of 10-20%(16,17). As our case had moderate ascites due to hepatic failure.

It has been suggested that prolongation of the prothrombin time in hepatic amyloidosis is unusual(18). However, a previous study found that 24% of patients with primary systemic amyloidosis had a prolonged prothrombin time(19). In multivariate analysis, a prolonged prothrombin time was the only coagulation abnormality associated with abnormal bleeding at sites other than the skin. Notably, the authors of that study did not report coagulation findings specific for patients with primary hepatic amyloidosis(19). However, we found that our patient with primary hepatic amyloidosis had a prolonged prothrombin time. These results suggest that

clinicians should monitor the prothrombin time of their patients who have primary hepatic amyloidosis, and if prothrombin time is prolonged, these patients should be closely observed for abnormal bleeding.

Many patients with primary amyloidosis have extrahepatic amyloid manifestations such as nephritic syndrome, heart failure, and peripheral neuropathy. But our patient did not show any other organ involvement.

Radiological findings of liver involvement are non-specific. Amorphous, or irregular calcifications were occasionally identified in the amyloid deposits. Ultrasonographic findings may show heterogeneous echogenicity(8). In contrast enhanced CT, some focal hypoattenuated areas in the liver with delayed enhancement may be seen(4,8).

In 60% of patients with primary amyloidosis, heart is involved and in 50% symptoms and signs of heart failure is a presenting feature. Cardiac amyloidosis is a leading cause of mortality and morbidity(20). In our patient echocardiography did not show any systolic or diastolic dysfunction.

Splenomegaly is seen in 10% of patients with amyloidosis. Also splenic infarction and rupture may be seen(2). Our case had normal spleen in ultrasonographic evaluation.

The non-specific nature of amyloidosis leads to delay in diagnosis. The diagnosis requires pathological confirmation of amyloidosis in tissue. Amyloid deposits can be found in bone marrow or subcutaneous aspirates in 85% of patients(6). However obtaining tissue from an affected organ with Congo red demonstrating amyloid deposits may be necessary. In our patient bone marrow pathology was normal, but liver biopsy tissue was

diagnostic for amyloidosis.

As noted above, our patient had only hepatic failure symptoms and signs, and laboratory studies revealed a marked deterioration of liver function with cholestatic pattern. But we do not have any document for other organ involvement. Bone marrow aspiration/biopsy, echocardiography, and renal function tests were all normal. In the abdominal ultrasonography, liver had mildly coarse echo pattern and spleen was normal.

The median survival of patients with primary hepatic amyloidosis has been reported as 9 months(4). Similarly, the overall median survival of patients in a case series was 8.5 months(18). Several studies suggest that patients with hepatic amyloidosis have poor prognoses if they have jaundice(7,12,15).Or an elevated concentration of bilirubin(11,14). In addition, multivariate analysis showed that two other factors were predictive of a poor prognosis: the presence of congestive heart failure before liver biopsy and a platelet count greater than  $500 \times 10^9/L$ .

Unfortunately the disease pattern in our patient was so progressive, as shortly after liver biopsy she died and chemotherapy was not initiated for her. It would be better if investigations for jaundice and liver biopsy performed earlier as without pathological confirmation no empiric therapy can be carried out.

## CONCLUSION

Because primary hepatic amyloidosis is a rare cause of abnormal results of liver function tests, clinicians may not consider amyloidosis as a cause of this finding. In case of an unexplained intrahepatic cholestasis and fulminant hepatic failure, the possibility of amyloidosis should be considered and a Congo red staining should be performed.

## REFERENCES

- Gertz M, Kyle R. Hepatic amyloidosis: Clinical appraisal in 77 patients. *Hepatology* 1997;25:118-21.
- Greipp PR. Amyloidosis (AL): An approach to early diagnosis. *Arch Intern Med* 1984;144:2145-6.
- Levy M, Fryd CH, Eliakim M. Intrahepatic obstructive jaundice due to amyloidosis of the liver: A case report and review of the literature. *Gastroenterology* 1971;61:234-8.
- Gertz MA, Kyle RA. Hepatic amyloidosis (primary [AL], immunoglobulin light chain): The natural history in 80 patients. *Am J Med* 1988;85:73-80.
- Shin YM. Hepatic amyloidosis. *Korean J Hepatol* 2011;17:80-3.
- Gertz M. Immunoglobulin light chain amyloidosis: 2014 update on diagnosis, prognosis, and treatment. *Am J Hematol* 2014;89:1132-40.
- Rubinow A, Koff R, Cohen A. Severe intrahepatic cholestasis in primary amyloidosis. A report of four cases and review of the literature. *Am J Med* 1978;64:937-46.
- Melkebeke P, Vandepitte J, Hannon R, Fevery J. Huge hepatomegaly, jaundice and portal hypertension due to amyloidosis of the liver. *Digestion* 1980;20:351-7.
- Rubio P, Farrell E, Lehane D. Primary liver amyloidosis producing obstructive jaundice. *South Med J* 1982;72:891-2.
- Cox R. Amyloidosis of the liver causing jaundice. *Postgrad Med J* 1982;58:1192-3.
- Melato M, Manconi R, Magris D, Morassi P, Benussi D, Tiribelli C. Different morphologic aspects and clinical features in massive hepatic amyloidosis. *Digestion* 1984;29:138-45.
- Finkelstein S, Fornasier V, Pruzanski W. Intrahepatic cholestasis with predominant pericentral deposition in systemic amyloidosis. *Hum Pathol* 1981;12:470-2.
- Konikoff R, Mor C, Stem S, Shaklai M, Halevy J, Theodor E. Cholestasis and liver failure with lambda-AL amyloidosis. *Gut* 1987;28:903-6.
- Hoffman N, Stein B, Davidan M, Rosenthal W. Hepatic amyloidosis presenting as severe intrahepatic cholestasis: A case report and review of the literature. *Am J Gastroenterol* 1988;83:783-5.
- Peters RA, Koukoulis G, Gimson A, Portmann B, Westaby D, Williams R. Primary amyloidosis and severe intrahepatic cholestatic jaundice. *Gut* 1994;35:1322-5.
- Levy M, Pollack A, Lender M. The liver in amyloidosis. *Digestion* 1974;10:40-51.
- Gregg J, Herskovic T, Bartholomew L. Ascites in systemic amyloidosis. *Arch Intern Med* 1965;116:605-10.
- Podolsky DK. Infiltrative, genetic, and metabolic diseases affecting the liver. In: Braunwald E, Fauci AS, Isselbacher KJ, editors. *Harrison's principles of internal medicine*. 15th ed. New York: McGraw-Hill; 2001:1766-70.
- Mumford AD, O'Donnell J, Gillmore JD, Manning RA, Hawkins PN, Laffan M. Bleeding symptoms and coagulation abnormalities in 337 patients with AL-amyloidosis. *Br J Haematol* 2000;110:454-60.
- Banypersad SM. Updates in Cardiac Amyloidosis: A Review. *J Am Heart Assoc* 2012;10:116-21.
- Kim SH, Han JK, Lee KH, Won HJ, Kim KW, Kim JS, et al. Abdominal amyloidosis: spectrum of radiological findings. *Clin Radiol* 2003;58:610-20.
- Mir-Madjlessi SH, Farmer RG, Hawk WA. Cholestatic jaundice associated with primary amyloidosis. *Cleve Clin Q* 1972;39:167-75.