

Appendicitis As a Complication of Acute Pancreatitis; A Case Report

Neda Nozari ^{1*}

¹ Gastroenterologist, Researcher, Digestive Disease Research Centre, Shariati Hospital, Tehran University of Medical Sciences, Tehran, Iran

ABSTRACT

Large bowel complications of acute pancreatitis are rare and always occur in the adjacent colon including transverse colon and splenic flexure colon. In this article, we report a 35-year-old man with acute pancreatitis (Ranson's score 2) who presented with severe abdominal pain in the emergency department. He had a history suggesting recent acute pancreatitis and also symptoms and signs of acute appendicitis at the time of admission. After primary cares, he underwent open appendectomy according to the computed tomography results. The report of pathology and analysis of the exudate around the appendix confirmed appendicitis as a complication of acute pancreatitis. This rare case report denotes that acute appendicitis was a complication of acute pancreatitis. However, more studies are required to define the relationship between pancreatitis and appendicitis.

Keywords: Acute pancreatitis, Acute appendicitis, Acute abdomen

please cite this paper as:

Nozari N. Appendicitis as a Complication of Acute Pancreatitis; A Case Report. *Govareh* 2016;21:199-201.

INTRODUCTION

Appendicitis and pancreatitis are among the most common causes of acute abdomen in patients referring to emergency rooms. Can appendicitis be a complication of pancreatitis or is it a mere coincidence of these two pathologies in one patient? In acute appendicitis, affected patient has nausea, vomiting, loss of appetite, and abdominal pain, similar to the signs of acute pancreatitis (1). We hereunder present a patient with signs of both appendicitis and pancreatitis.

**Corresponding author:*

Neda Nozari, MD

Shahid Rajai Hospital, Alborz University of Medical Sciences, Karaj, Iran

Telefax: +98 26 34570029-30

E-mail: nozari_neda@yahoo.com

Received: 02 Jul. 2016

Edited: 18 Aug. 2016

Accepted: 19 Aug. 2016

CASE REPORT

A 35-year-old man was visited in the emergency room for severe abdominal pain, loss of appetite, nausea, and vomiting since one week earlier. During the one week, the pain was continuous mostly in the epigastric region with radiation to the back. The patient did not have a history of alcohol consumption, drug addiction, or certain diseases. On physical examination, the patient was alert but tachycardic and febrile. He had a painful rigid abdomen, which was tender predominantly in right lower quadrant with positive rebound tenderness. Laboratory results were as follows: White blood cell: 17×10^9 per liter (80% neutrophils), hematocrit: 42%, platelet count: 250×10^9 /L, C-reactive protein: 4 g/dL, erythrocyte sedimentation rate: 35 mm/hr, blood urea nitrogen: 18mg/dL, creatinine: 0.7 mg/dL, triglycerides: 750 mg/dL, lactic acid dehydrogenase: 450U/L, aspartate aminotransferase: 105 U/L, alanine aminotransferase: 97 U/L, total bilirubin: 1mg/dL, calcium: 9mg/dL, amylase: 1050 U/L, lipase: 20 U/L, albumin: 4mg/dL, glucose: 180 mg/dL, PO₂: 90mmHg, base deficit: 3mEq/L.

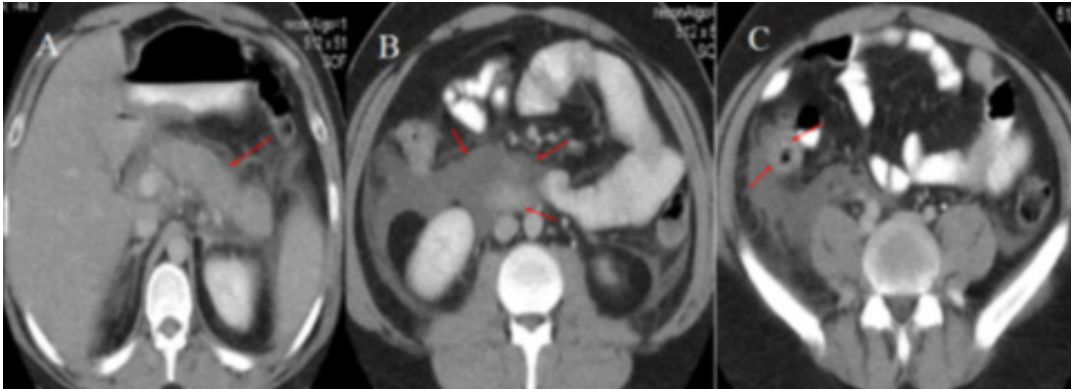


Fig. 1: Abdominal CT scan, evidence of inflammation in the pancreas (A) with fluid accumulation in the mesentery (B) and around the inflamed appendix (C).

The results of laboratory tests were negative for blood, stool, and urine cultures. Chest radiograph was normal with no evidence of pleural effusion. Because the findings of physical examination and laboratory results were not congruent, abdominal computed tomography (CT) was requested, which revealed the evidence of complicated pancreatitis along with fluid accumulation around the inflamed appendix (figure 1). After primary intervention and starting antibiotic therapy, the patient underwent appendectomy. Pathological examination confirmed the evidence of severe appendicitis and analysis of the abdominal exudate showed the presence of amylase and lipase in the fluid surrounding the appendix. The patient received supportive care during hospital admission and was discharged after one week in good health. On one-month follow-up, considering the fasting triglyceride level above 1000 mg/dL, gemfibrozil was started for the patient and he was advised to follow a diet. On 3-month follow-up, serum triglyceride was controlled and no other complications were noticed.

DISCUSSION

Although the increase in amylase and lipase levels more than 3-folds of the normal range in addition to a typical history and physical examination are adequate for a clinical diagnosis of pancreatitis, it should be noted that serum amylase is also elevated in other cases of abdominal pain, such as appendicitis (2). Serum lipase is more valuable in the diagnosis of acute pancreatitis but it is not specific either and its elevated levels are observed in other pathologies, like appendicitis. The level of serum amylase usually

returns to normal values during 3-5 days after the onset of acute pancreatitis. In our patient, high levels of serum amylase one week after the onset of the symptoms of pancreatitis seem to be resulted from local complications of pancreatitis because patients with delayed form of acute pancreatitis (more than one week after the onset of symptoms) usually develop local complications (3). Imaging of the pancreas with intravenous contrast CT is a diagnostic criterion when there is clinical suspicion and also to evaluate its complications (3,4). Moreover, CT is more accurate and more specific and sensitive than ultrasonography for detecting appendicitis in adult patients (4). In general, the large intestine complications of pancreatitis are not more than 7%, including infarction, infection, and transverse colon and splenic flexure fistula, and isolated involvement of the appendix as a complication of pancreatitis has not been reported in the literature (1,5). However, according to the reports of rare cases, there is a probability that appendicitis be a rare complication of mild pancreatitis (1,4,5). Due to the evidence of peritonitis resulting from appendicitis, our patient underwent appendectomy and received antibiotic treatment in addition to supportive care for acute pancreatitis. However, there are reports of supportive and maintenance treatment (including somatostatin analogue administration without surgical intervention) for the treatment of appendicitis with peritoneal involvement as a complication of pancreatitis (4). The report of the pathological evaluation and analysis of the exudate around the appendix confirmed appendicitis as a complication of acute pancreatitis in our patient. However, more

studies are required to clear the relationship between pancreatitis and appendicitis. Is it possible that the infection is transferred from the pancreas to the colon or vice versa? What treatment (supportive care with or without surgical intervention) is more appropriate for such patients when the peritoneum is involved (1)?

REFERENCES

1. Alaqgad M, Ram L, Kannan P, Abou Al Neaj M. Pancreatitis complicated by acute appendicitis. *Hamdan Med J* 2015;8:161-4.
2. Forster M, Akoh J. Perforated appendicitis masquerading as acute pancreatitis in a morbidly obese patient. *World J Gastroenterol* 2008 ;14:1795-6.
3. Tenner S, Baillie J, Dewitt J, Vege SS. American college of gastroenterology guideline :management of acute pancreatitis. *Am J Gastroenterol adv Online Pub* 2013.
4. Wasnik N, Agrawal VP, Khatri KR, Khatri V. Acute pancreatitis masquerading as acute appendicitis – a diagnostic dilemma. *IJBAR* 2013; 4.
5. Hsia HC, Shoung LK, Wong DW. Acute pancreatitis complicated with periappendicitis. *Zhonghua Yi Xue Za Zhi (Taipei)* 2002; 65:619-21.[Abstract]