

Chest computed angiography or magnetic resonance imaging (MRI) confirms the vascular cause of external compression on esophagus but the gold standard of diagnosis is arteriography (11). Surgical intervention is recommended for symptomatic patient with dysphagia or GI bleeding (12) but most patients remain asymptomatic.

In the present case, after confirmation of vascular anomaly by angiography, we just recommended to modify her eating style and reassured her. In one-month follow-up, her symptoms were significantly subsided without any further intervention.

R. Adult-onset dysphagia lusoria secondary to a dissecting aberrant right subclavian artery associated with type B acute aortic dissection. *Canadian J Cardiol* 2008;24:63-5.

REFERENCES

1. Natsis KI, Tsitouridis IA, Didagelos MV, Fillipidis AA, Vlasis KG, Tsikaras PD. Anatomical variations in the branches of the human aortic arch in 633 angiographies: clinical significance and literature review. *Surg Radiol Anat* 2009;31:319-23.
2. Jakanani GC, Adair W. Frequency of variations in aortic arch anatomy depicted on multidetector CT. *Clin Radiol* 2010;65:481-7.
3. Müller M, Schmitz BL, Pauls S, Schick M, Röhrer S, Kapapa T, et al. Variations of the aortic arch—a study on the most common branching patterns. *Acta Radiol* 2011;52:738-42.
4. Karacan A, Türkvatan A, Karacan K. Anatomical variations of aortic arch branching: evaluation with computed tomographic angiography. *Cardiol Young* 2014;24:485-93.
5. Janssen M, Baggen MG, Veen HF, Smout AJ, Bekkers JA, Jonkman JG, Ouwendijk RT. Dysphagia lusoria: clinical aspects, manometric findings, diagnosis, and therapy. *Am J Gastroenterol* 2000;95:1411-6.
6. Zapata H, Edwards JE, Titus JL. Aberrant right subclavian artery with left aortic arch: associated cardiac anomalies. *Pediatr Cardiol* 1993;14:159-61.
7. Hunauld NA. Examen de quelques parties d'un signe. *Hist Acad R Sci* 1735;2:516-23.
8. Bayford D. An account of a singular case of obstructed deglutition. *Med Soc London*; 1787.
9. Myers PO, Fasel JH, Kalangos A, Gailloud P. Arteria lusoria: developmental anatomy, clinical, radiological and surgical aspects. *Ann Cardiol Angeiol (Paris)* 2010;59:147-54.
10. Pramesh CS. Injury of an aberrant subclavian artery: a rare complication of video assisted thoracoscopic esophagectomy. *Ann Thorac Cardiovasc Surg* 2005;11.
11. Kau T, Gasser J, Lesnik G, Sinzig M, Hausegger KA. Images in vascular medicine. *Vas Med* 2008;13:89-90.
12. Singh S, Grewal PD, Symons J, Ahmed A, Khosla S, Arora

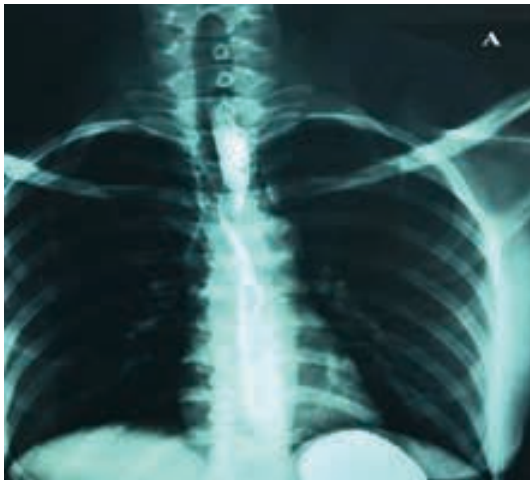

Fig.A: Barium swallow, anterior view.

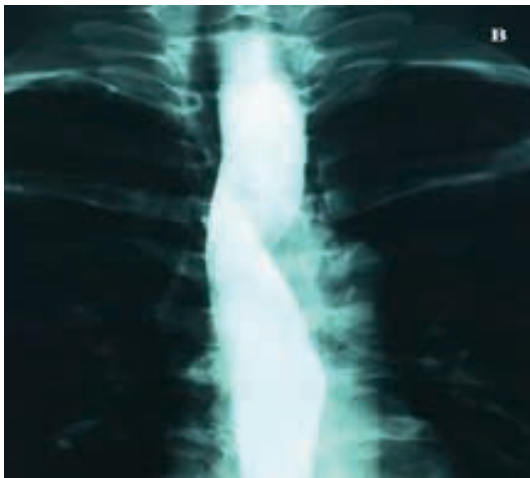

Fig.B: Barium swallow, anterior view.

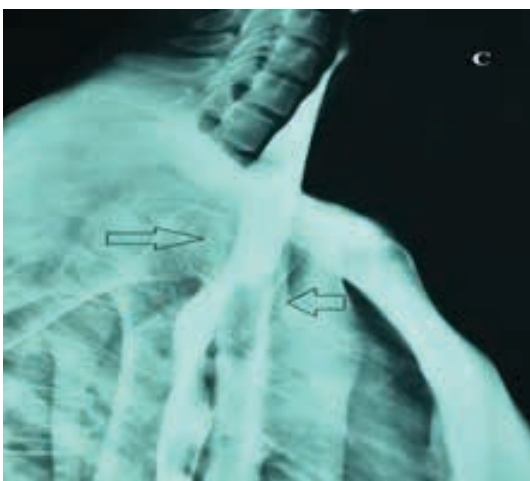

Fig.C: Barium swallow, lateral view.

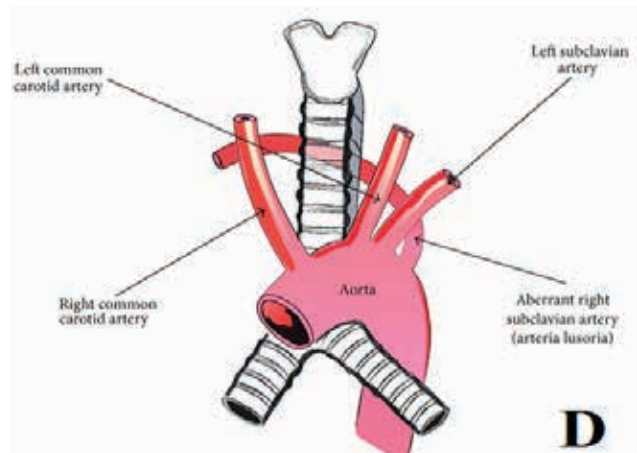


Fig.D: Schematic image of aberrant right subclavian artery.

common anomaly of the aortic arch is occurring in 0.5-2.5% of individuals (6). It is the first arch anomaly, which was described in 1735 by Hunauld (7). Dysphagia caused by an aberrant right subclavian artery first described by David Bayford, who called the clinical syndrome as dysphagia lusoria and the aberrant artery causing it as arteria lusoria (8).(figure D)

Dysphagia lusoria is an impairment of swallowing caused by compression from an aberrant right subclavian artery. The right subclavian artery will arise as the last branch of the aortic arch if the proximal portion of the right fourth arch disappears instead of the distal portion during the fetal development of aortic arch. It then courses behind the esophagus to supply blood to the right arm. This causes pressure on esophagus and could results in dysphagia. It sometimes can even result in upper GI tract bleeding (4,5,9).

The dysphagia may be mild and chronic or mild and recurrent. It may become progressively worse or it may be fairly severe with acute exacerbations. The dysphagia is mainly for solid foods, but it can also be for liquids if taken fast. There is no pain, and the swallowing-time is usually normal (10). Two thirds of individuals are believed (on the basis of autopsy studies and retrospective studies) to remain completely asymptomatic despite the anomaly. There are a few proposed mechanisms as to why certain individuals become symptomatic:

- (1) Increased esophageal rigidity with ageing,
- (2) Aneurysm formation,
- (3) Aortic elongation with ageing,
- (4) The presence of a bicarotid trunk.

Dysphagia Caused by Vascular Anomaly; A Case Report

Pezhman Alavinejad ^{1*}, Kaveh Ebadi Borna ²

¹ Gastroenterologist, Research Center for Infectious Diseases of Digestive System, Ahvaz Jundishapur University of Medical Sciences, Ahvaz, Iran

² Fellowship of Gastroenterology, Gastrointestinal Ward, Ahvaz Jundishapur University of Medical Sciences, Ahvaz, Iran

ABSTRACT

One of the rare causes of dysphagia is vascular malformation due to abnormal origin of right subclavian artery. This vascular abnormality, which is originated during embryonic development, is usually asymptomatic and is found incidentally. Herein we present a 36-year-old lady with the complaint of dysphagia who was diagnosed as having dysphagia lusoria caused by aberrant right subclavian artery. With reassurance and treatment of symptoms, her symptoms completely relieved without any further intervention.

Keywords: Dysphagia, Vascular malformation, Lusoria, Subclavian artery

please cite this paper as:

Alavinejad P, Ebadi Borna K. Dysphagia Caused by Vascular Anomaly; A Case Report. *Govareh* 2016; 21:202-204.

INTRODUCTION

Approach to dysphagia usually starts with barium radiography after taking a focused history. Alternatively, endoscopy has been advocated as the first step, especially among patients who complain intermittent dysphagia by solid foods suggestive of a lower esophageal ring or with pronounced reflux symptoms. Although common causes of dysphagia are mostly related to reflux disease and peptic strictures, achalasia, esophageal malignancies, or motility disorders, responsible physicians should always be aware of benign conditions to prevent any unnecessary intervention. For this reason familiarity with adjacent structures specially aortic arch and its common vascular abnormalities including abnormal

right subclavian artery, which may indent the esophageal wall is mandatory (1,2). Variations of the aortic arch and its branches are present in 2-3% of the population but they rarely produce symptoms of esophageal obstruction despite evident vascular compression showing on an esophagogram. They are mostly present as incidental findings during routine diagnostic scanning (3-5).

CASE REPORT

A 36-year-old woman was referred to gastrointestinal (GI) clinic with the complaint of intermittent dysphagia since 3 months earlier, which was aggravated on swallowing of large or hard food particles. The patient did not have any history of recent weight loss, dyspepsia, and or positive family history. Her drug history was also negligible. An upper endoscopy and barium swallow was requested for the patient. The endoscopy described esophagus with normal findings but her barium swallow study revealed an oblique filling defect in the proximal third of the esophagus (figures A, B). There was also an indentation on its posterior-lateral aspect, which was caused by the compression of esophagus by the aberrant right subclavian artery (figure C).

DISCUSSION

The aberrant right subclavian artery as the most

*Corresponding author:

Pezhman Alavinejad, MD

Gastrointestinal Department, Ahvaz Imam Hospital, Ahvaz, Iran

Telefax: +98 613 2921839

Email: pezhmanalavinejad@gmail.com

Received: 05 May 2016

Edited: 08 Aug. 2016

Accepted: 09 Aug. 2016