

Achalasia in a Patient with Multiple Myeloma: a Case Report

Anahita Sadeghi¹, Pouya Bastani², Mehdi Mohamadnejad^{3,*}

¹ Digestive Disease Research Center, Digestive Disease Research Institute, Tehran University of Medical Sciences, Tehran, Iran

² Department of Internal Medicine, Shariati Hospital, Tehran University of Medical Sciences, Tehran, Iran

³ Liver and Pancreatobiliary Research Center, Digestive Disease Research Institute, Tehran University of Medical Sciences, Tehran, Iran

ABSTRACT

Achalasia is a medical condition presenting with dysphagia to both liquids and solids. Although it is usually a primary disease, there are cases in which achalasia occurs secondary to other conditions. Despite its presentation as a secondary condition in a number of diseases, it is very rare for achalasia to be associated with multiple myeloma especially as the presenting symptom when the patient's disease has not been diagnosed yet. Initial manifestations of multiple myeloma include array of symptoms such as back pain, bone lesions, and anemia, but as mentioned before it is extremely rare for it to initially present with achalasia.

Here we describe a man who initially presented with dysphagia and further studies confirmed the diagnosis of achalasia. Later he was diagnosed as having multiple myeloma following other presentations of the disease, thus making the dysphagia caused by achalasia his presenting symptom of multiple myeloma.

Keywords: Achalasia, Dysphagia, Multiple myeloma, Anemia

please cite this paper as:

Sadeghi A, Bastani P, Mohamadnejad M. Achalasia in a Patient with Multiple Myeloma: a Case Report. *Govaresh* 2018;22:271-273..

INTRODUCTION

Achalasia is a condition most commonly associated with dysphagia to solid and fluid materials. It has unique imaging presentations and is distinguished by patients' history, a barium study, and manometric studies. In some cases, which comprise a very small portion of patients with the condition, achalasia can occur secondary to other diseases such as carcinomas (1,2).

Endoscopic ultrasonography (EUS) is a valuable method for differentiating pseudoachalasia from

achalasia because of its more accurate image and providing the ability to take a biopsy (3). Here we present a patient who was initially diagnosed as having achalasia and was later found to have multiple myeloma.

CASE REPORT

A 60-year-old man, presented to our gastroenterology clinic with the chief complaint of having difficulty in swallowing solid foods since two years earlier, which progressed to liquids. After 6 months of treatment with oral proton pump inhibitor (omeprazole) 20 mg, the symptom did not improve and an upper gastrointestinal (GI) endoscopy was performed revealing a mild esophagitis. The dose of omeprazole was increased but his dysphagia did not improve. 6 months later, the patient developed low back pain, and anemia. Multiple myeloma was diagnosed with the presence of monoclonal gamma globulin peak on serum protein electrophoresis, lytic bone lesions, and the presence of more than 30% of plasma cells on bone marrow examination. Melphalan, thalidomide, and prednisolone were

*Corresponding author:

Mehdi Mohamadnejad, MD

Liver and Pancreatobiliary Center, Digestive Disease Research Institute, Tehran University of Medical Sciences, Tehran, Iran

Telefax: + 98 21 82415104

Email: mehdi.nejad@gmail.com

Received: 03 Sep. 2017

Edited: 29 Nov. 2017

Accepted: 30 Nov. 2017

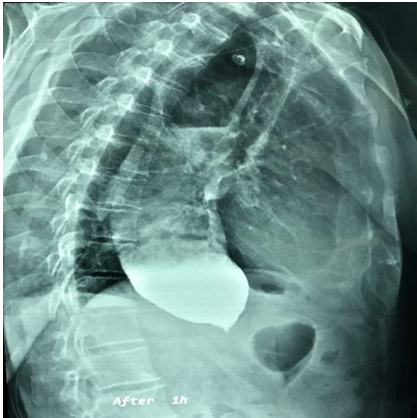


Fig.1: Barium study showing a significantly dilated esophagus and the characteristic bird beak appearance at distal esophagus.

administered as his chemotherapy regimen. In view of his progressive dysphagia, which did not respond to omeprazole, the patient underwent another session of upper GI endoscopy. On endoscopy, the distal esophagus was filled with undigested food and the lower esophageal sphincter (LES) was spastic. There was no tumoral mass lesion on upper GI tract. Biopsy samples were taken from distal esophageal mucosa, which revealed histological changes consistent with reflux esophagitis with no dysplasia. In microscopic study of one of the biopsy samples, a thick bundle of smooth muscle was seen in muscularis mucosa. Timed barium esophagogram revealed significantly dilated esophagus and the bird's beak deformity at distal esophagus consistent with achalasia (figure 1). The findings of esophageal manometry was consistent with type I achalasia, revealing a hypertensive LES at rest and severe stricture, which obstructed the passage of the catheter from the esophagus to the stomach, thus esophagogastric junction (EGJ) outflow obstruction and type I (classic) achalasia in conjunction with clinical, endoscopic, and imaging findings was concluded. EUS revealed no mass lesion at or around the gastroesophageal junction. The muscularis mucosa of the lower esophagus was thickened. EUS guided fine needle aspirate was taken from the thickened muscularis mucosa, which revealed no malignant cells on cytology. These findings confirmed the diagnosis of achalasia and the patient underwent endoscopic pneumatic balloon dilation. His dysphagia resolved after the procedure and the patient remained

asymptomatic after 2 months of follow-up.

DISCUSSION

Multiple myeloma is a monoclonal neoplastic proliferation of plasma cells diagnosed by the presence of more than 10% plasma cells in bone marrow, along with a monoclonal gamma peak in serum protein electrophoresis, and end organ damage including lytic bone lesions, renal failure, and hypercalcemia. It almost invariably involves bone marrow causing many disturbances most commonly in kidneys, calcium homeostasis, and bones as well as anemia (4). In the literature there are many case reports regarding unusual manifestations of multiple myeloma including carpal tunnel syndrome, arthritis (5), spontaneous hypoglycemia (6), and so on. Multiple myeloma can result in amyloid light chain (AL) amyloidosis and its involvement of the GI tract has been shown to be dominantly in the small intestine thus having manifestations such as diarrhea, and malabsorption (7). Although there have been case reports of amyloidosis involving the esophagus and the stomach (8) the evidence of such occurrence in relation to multiple myeloma so limited. However, we were able to find a case report about a patient with dysphagia consistent with achalasia that was later found to have amyloid deposition in the esophagus and was diagnosed as having multiple myeloma (9). With regard to our literature review it is so uncommon for a patient with undiagnosed multiple myeloma similar to our patient, to present with symptoms of achalasia, which could not be explained by any other disease process.

CONFLICT OF INTEREST

The authors declare no conflict of interests related to this work.

REFERENCES

1. Tucker HJ, Snape WJ Jr, Cohen S. Achalasia secondary to carcinoma: Manometric and clinical features. *Ann Intern Med* 1978;89:315-8.
2. Lahbabi M, Ihssane M, Sidi Adil I, Dafr Allah B. Pseudoachalasia secondary to metastatic breast carcinoma mimicking radiation stenosis. *Clin Res Hepatol Gastroenterol* 2012;36:e117-21.
3. Bryant RV, Holloway RH, Nguyen NQ. Education and imaging. *Gastrointestinal: Role of endoscopic ultrasound*

in the evaluation of pseudoachalasia. *J Gastroenterol Hepatol* 2012;27:1128.

4. Kyle RA, Gertz MA, Witzig TE, Lust JA, Lacy MQ, Dispenzieri A, et al., Review of 1027 Patients With Newly Diagnosed Multiple Myeloma. *Mayo Clin Proc* 2003;78:21-33.
5. Molloy CB, Peck RA, Bonny SJ, Jowitt SN, Denton J, Freemont AJ, et al. An unusual presentation of multiple myeloma: a case report. *J Med Case Rep* 2007;1:84.
6. Heffernan AG. Unusual presentation of multiple myeloma. *Postgrad Med J* 1972;48:238-40.
7. Ebert EC, Nagar M. Gastrointestinal Manifestations of Amyloidosis. *Am J Gastroenterol* 2008;103:776-87.
8. Shatnawei, Abdullah, Vijaya Dasari, John Dumot, and Donald F. Kirby Two Cases of Gastric and Esophageal Amyloidosis. *J Gastroenterol Hepatol* 2009;5:571-4.
9. Lazaraki G, Nakos A, Katodritou E, Pilpilidis I, Tarpagos A, Katsos I. A rare case of multiple myeloma initially presenting with pseudoachalasia. *Dis Esophagus* 2009;22:E21-4.