

Adult Primary Intestinal Lymphangiectasia; A Case Report

Ali Beheshti Namdar¹, Maryam Esmailpour^{2,*}, Mitra Ahadi³

¹ Assistant Professor, Gastroenterology and Hepatology Research Center, Mashhad University of Medical Sciences, Mashhad, Iran

² Resident of Internal Medicine, Student Research Committee, Mashhad University of Medical Sciences, Mashhad, Iran

³ Associate professor, Gastroenterology and Hepatology Research Center, Mashhad University of Medical Sciences, Mashhad, Iran

ABSTRACT

Primary intestinal lymphangiectasia is a rare congenital disorder leading to edema, hypoproteinemia, lymphocytopenia, and watery diarrhea. We here report a case of primary intestinal lymphangiectasia in a woman with peripheral edema and recurrent diarrhea in whom laparoscopic biopsy confirmed the diagnosis. In this report, a 21-year-old woman was referred to a tertiary hospital because of abdominal pain, lower extremity edema, and a history of chronic watery diarrhea from childhood. The patient was diagnosed as having protein losing enteropathy secondary to intestinal lymphangiectasia. Diagnosis was confirmed by laparoscopy and multiple deep intestinal biopsies were performed. The diagnosis of primary intestinal lymphangiectasia is usually neglected especially in adults. This differential diagnosis should be considered in any patients with a history of chronic diarrhea and hypoproteinemia. The correct clinical suspicion can properly guide physicians to the correct diagnosis. Diet intervention is the cornerstone of the medical management of primary intestinal lymphangiectasia, which is affected strongly with timely diagnosis.

Keywords: Primary intestinal lymphangiectasia, Hypoproteinemia, Chronic diarrhea, Edema

please cite this paper as:

Beheshti Namdar A, Esmailpour M, Ahadi M. Adult Primary Intestinal Lymphangiectasia; A Case Report. *Govaresh* 2019;23:265-268.

INTRODUCTION

Primary intestinal lymphangiectasia is a rare medical condition presenting with hypoproteinemia, low serum albumin, and reduced gammaglobulin levels, which was introduced first by Waldman and colleagues in 1961 (1). The underlying pathology is intestinal lymphatic drainage impairment, which results from dilated and tortuous lymphatics. This unnatural lymphatic arrangement leads to leakage of lymph and protein-rich chyle into the intestinal lumen, causing

protein-losing gastroenteropathy, lymphopenia, hypoalbuminemia, and hypogammaglobulinemia, and finally peripheral or mucosal edema (2). Protein excretion causes an immune system disorder, which includes hypogammaglobulinemia and the development of skin disorders.

Patients usually present with persistent diarrhea and peripheral edema, which may be unilateral or bilateral (in the primary type of the disease, the edema is always bilateral). Visual acuity is reduced due to macular edema. Other common symptoms in this disease are osteoarthritis, lymphocytopenia, hypogammaglobulinemia, hypoproteinemia, and malabsorption. The exact mechanism for protein excretion from the intestine is not precisely defined, but it seems that increased pressure in the lymphatic channels is involved (2,3). Ultrasound findings include the dilatation of the intestinal loops and the diffused and regular increase of the intestinal wall and mesenteric edema along with chylous ascites, which could be found in abdominal computed tomography with wall thickening, mesenteric "edema", or ascites (4-7).

*Corresponding author:

Maryam Esmailpour, MD

Central Headquarter of Mashhad University of Medical Sciences, University street, Mashhad, Iran

Tel: + 98 51 38049

Fax: + 98 5138713638

Email: EsmailpourM941@mums.ac.ir

Received: 15 Apr. 2018

Edited: 05 Sep. 2018

Accepted: 06 Sep. 2018

Different methods of imaging and procedures such as endoscopy, endoscopic capsule, and biopsy are used to diagnose the disease (4, 8-9). Occurrence of a creamy and yellowish state in the jejunum villi is a macroscopic manifestation of the disease due to the dilatation of the lymphatic vessels in the intestine. The specific diagnostic laboratory method is the measurement of alpha-1-antitrypsin clearance in the 24-hour stool, which is increased in the disease (2).

In this report, we have introduced a young woman who complained of chronic watery diarrhea and peripheral edema, in whom performing necessary examinations led to the diagnosis of early intestinal lymphangiectasis in her third decade of life. Due to multiple dramatic symptoms and complications, the disease is mostly diagnosed by pediatricians in the early years of life (early childhood). Therefore, the diagnosis of primary intestinal lymphangiectasis in adults is unusual and rare.

CASE REPORT

A 21-year-old woman was referred with the complaint of abdominal pain and edema. Abdominal pain was localized in the periumbilical region, which was not related to eating, but was associated with defecation. Also, chronic watery diarrhea, nausea, and vomiting existed. Other symptoms like fever and weight loss were not mentioned. The patient reported no particular medical history in the past. In the head and neck examination, periorbital edema and in the abdominal examination, abdominal distention secondary to ascites was found. In the examination of the lower limbs, pitting edema was observed up to the knee. In laboratory and paraclinical examinations, normocytic anemia, hypoalbuminemia, hypoproteinemia, and ascites were observed. The number of white blood cells, platelets, liver tests, smear samples, stool culture, and thyroid function were reported to be normal. All serological laboratory tests for celiac disease were also negative. Ultrasound of the liver and bile ducts and the renal system was normal. Mild pericardial effusion was reported in echocardiography. The patient was scheduled for endoscopic evaluation to rule out the causes of malabsorption. In upper endoscopy, minor nodularity was observed in the gastric antrum. The biopsy samples taken from stomach were sent to a

pathology laboratory. The histological examination revealed chronic gastritis and duodenitis without atrophy and dysplasia. A biopsy sample of the duodenum was taken despite the normal macroscopic appearance, which was also reported to be normal. Also, the patient underwent colonoscopy for the assessment of chronic diarrhea; however, the colon was normal. The double balloon enteroscopy was not available in public health sector and its costs was high in private sector, therefore, the patient received push enteroscopy with biopsy, which showed no specific clinical and pathological changes. Because of negative results of previous procedures, the patient underwent a diagnostic laparoscopy –as a minimally invasive method-, in which due to the swelling of the small intestine arches, multiple full thickness biopsy samples of the intestine were taken and the samples were sent for histological examination.

Histological examination confirmed the dilatation of lymphatic vessels in the intestinal mucosa and the diagnosis of intestinal lymphangiectasis. Due to the absence of any of the secondary causes (such as pericarditis, lymphoma, scleroderma, and sarcoidosis), the final diagnosis of primary intestinal lymphangiectasis was, therefore, confirmed and the treatment was initiated for the patient. Figure 1 shows the histologic examination of bowel tissue.

DISCUSSION

In several reports of primary intestinal lymphangiectasis in recent years, the disease has been described mostly in the early stages of life. In a case report published in 2013, a 17-year-old girl of the Mogul race was introduced who was referred to the hospital with diarrhea and edema symptoms, and was eventually diagnosed with intestinal lymphangiectasis after performing multiple biopsies of the small intestine by double balloon enteroscopy. The patient was then received the treatment with full venous nourishment in the hospital, and the symptoms of the disease completely abated by the continued oral therapy with a low-fat diet and medium-chain triglycerides. Due to the occurrence of symptoms and the diagnosis of the disease in the early stages of life, the observation of primary causes in later age groups is not expected (2). The presentation of intestinal lymphangiectasis in adulthood could consider as an

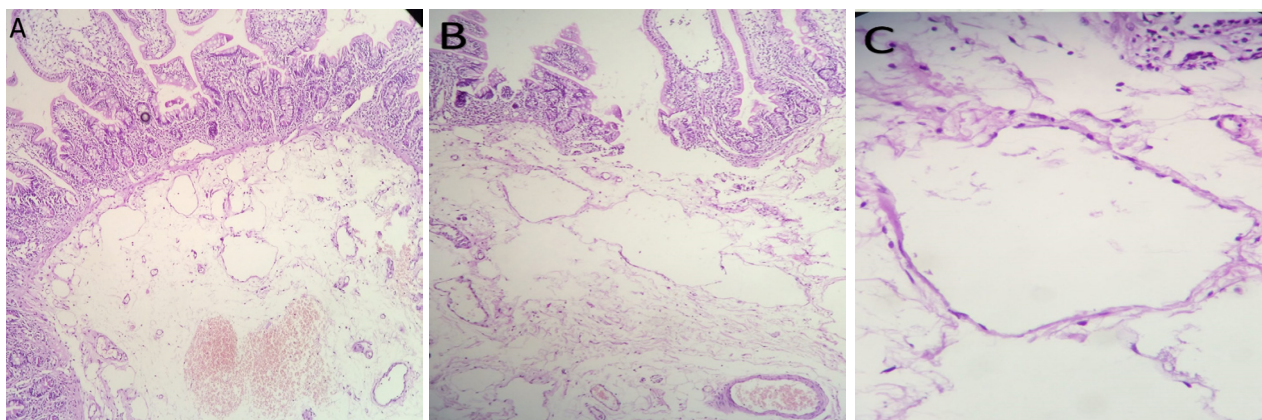


Fig.1: A.Intestinal mucosa with dilated lymphatic beneath the epithelium and in lamina proper, H&E staining.100X. B.Intestinal mucosa with dilated lymphatic beneath the epithelium and in lamina proper, H&E staining.400X

uncommon presentation, however, there are series reported this diagnosis in a 83-year-old woman (10), a 36-year-old man (11), and a 15-year-old boy (12).

In our patient, the first manifestations were peripheral edema, non-specific pain in the abdominal region, and watery diarrhea. A detailed biography of the patient's diet and medications was recorded. Various experiments were conducted to rule out infectious causes. Urine, stool, and blood cultures were negative (2). The patient was examined for hypoproteinemia. No protein excretion from the urinary system was found. The patient then underwent upper endoscopy and colonoscopy, and superficial biopsy samples were taken several times, which were not diagnostic and the causes of malabsorption such as celiac disease were excluded. Finally, the patient scheduled for a diagnostic laparoscopy. Because of swelling in the intestinal loops, deep biopsies of the intestinal tissue were performed and in the pathological evaluation, dilation of lymphatic vessels and intestinal lymphangiectasia were diagnosed. Due to the fact that, for this patient, a full thickness biopsy sample was taken during laparoscopy and this method is more reliable than other less invasive diagnostic methods, it is suggested that in case of strong clinical suspicion while other methods of diagnosis are negative, other options, including diagnostic laparoscopy, could also be used, because superficial biopsy with routine techniques, for example during endoscopy was not diagnostic in this specific patient. The main treatment of this disease is a low-fat diet and

the use of medium-chain triglycerides. Anti-plasmin compounds such as tranexamic acid and octreotide are used in the treatment of this disease, and in cases with severe edema, albumin transfusion is used (2).

CONCLUSION

Due to the occurrence of symptoms of primary intestinal lymphangiectasia in early childhood or younger ages, and given that in the absence of a timely diagnosis and treatment of the disease, there will be several consequences and complications for the affected patients, it is necessary that physicians consider a strong clinical suspicion to diagnose the disease even in adult patients. By performing careful screening and timely diagnosis and treatment, the symptoms of the disease can be relieved and the patient's quality of life will be improved.

CONFLICT OF INTEREST

The authors declare no conflict of interests related to this work.

REFERENCES

1. Waldmann TA, Steinfeld JL, Dutcher TF, Davidson JD, Gordon RS. The role of the gastrointestinal system in "idiopathic hypoproteinemia". *Gastroenterology* 1961;41:197-207.
2. Vignes S, Bellanger J. Primary intestinal lymphangiectasia (Waldmann's disease). *Orphanet J Rare Dis* 2008;3:5.
3. Mistilis SP, Skyring AP, Stephen DD. Intestinal lymphangiectasia. Mechanism of enteric loss of plasma-protein and fat. *Lancet* 1965;1:77-9.

4. Freeman HJ, Nimmo, M. Intestinal lymphangiectasia in adults. *World J Gastrointest Oncol* 2011;3:19-23.
5. Maconi G, Molteni P, Manzionna G, Parente F, Bianchi Porro G. Ultrasonographic features of long-standing primary intestinal lymphangiectasia. *Eur J Ultrasound* 1998;7:195-8.
6. Yang DM, Jung DH. Localized intestinal lymphangiectasia: CT findings. *AJR Am J Roentgenol* 2003;180:213-4.
7. Mazzie JP, Maslin PI, Moy L, Price AP, Katz DS. Congenital intestinal lymphangiectasia: CT demonstration in a young child. *Clin Imaging* 2003;27:330-2.
8. Liu NF, Lu Q, Wang CG, Zhou JG. Magnetic resonance imaging as a new method to diagnose protein losing enteropathy. *Lymphology* 2008;41:111-5.
9. So Y, Chung JK, Seo JK, Ko JS, Kim JY, Lee DS, et al. Different patterns of lymphoscintigraphic findings in patients with intestinal lymphangiectasia. *Nucl Med Commun* 2001;22:1249-54.
10. Cappell MS, Edhi A, Amin M. Case report of primary intestinal lymphangiectasia diagnosed in an octogenarian by ileal intubation and by push enteroscopy after missed diagnosis by standard colonoscopy and EGD. *Medicine (Baltimore)* 2018;97:e9649.
11. Lee SJ, Song HJ, Boo SJ, Na SY, Kim HU, Hyun CL. Primary intestinal lymphangiectasia with generalized warts. *World J Gastroenterol* 2015;21:8467-72.
12. Surampalli V, Ramaswamy S, Surendran D, Bammigatti C, Swaminathan RP. Primary Intestinal Lymphangiectasia (Waldmann's Disease) Presenting with Chylous Effusions in a 15-Year-Old. *J Clin Diagn Res* 2017;11:OD17-OD18.