

Duodenal Variceal Bleeding: A Rare Case of Upper Gastrointestinal Bleeding

Nader Roushan¹, Omid Eslami^{1,2,*}, Reza Taslimi¹, Seyed Farshad Allameh¹

¹ Gastroenterology Ward, Imam Khomeini Hospital, Tehran University of Medical Sciences, Tehran, Iran

² Kerman University of Medical Sciences, Kerman, Iran

ABSTRACT

Upper gastrointestinal bleeding (UGIB) is a common medical condition that presents with hematemesis (vomiting of blood or coffee ground -like material) and/or melena (black, tarry stools). Gastroduodenal ulcer disease, erosive esophagitis, esophagogastric varices, and erosive gastritis/duodenitis account for most of the cases. Ectopic varices are varices develop at sites other than the esophagus and stomach for example duodenal, rectal, and peristomal varices. Ectopic varices are relatively rare; however, approximately 5% are related to gastrointestinal bleeding. Duodenal variceal bleeding is a rare cause of gastrointestinal bleeding. Here we report a case of UGIB due to duodenal varices in a 44-year-old woman who admitted to the hospital because of melena, nausea, and vomiting from 3 weeks earlier. Two esophagogastroduodenoscopic examination and one colonoscopic examination were normal. Computed tomography (CT) of the abdomen revealed ectopic varices in the duodenum. Endoscopic cyanoacrylate was injected and bleeding was controlled. The patient did not experience rebleeding after one month.

Keywords: Ectopic varix, Gastrointestinal bleeding, Cyanoacrylate

please cite this paper as:

Roushan N, Eslami O, Taslimi R, Allameh SF. Duodenal Variceal Bleeding: A Rare Case of Upper Gastrointestinal Bleeding. *Govaresh* 2018;23:193-196.

INTRODUCTION

Acute upper gastrointestinal bleeding (UGIB) is characterized by hematemesis or melena or both (1). Gastroduodenal ulcer disease, erosive esophagitis, esophagogastric varices, and erosive gastritis/duodenitis account for the most of the cases. Ectopic varices are a term reserved for varices, which exist outside the esophagogastric region (2). Up to 17% of ectopic varices occur in the duodenum, but they are not a common cause of variceal bleeding (3).

***Corresponding author:**

Omid Eslami, MD

Endoscopic ward, Imam Khomeini Hospital Complex, Keshavarz Blv, Tehran, Iran

Telefax: + 98 21 66581650

Email: o_eslami@yahoo.com

Received: 10 Jun. 2018

Edited: 19 Aug. 2018

Accepted: 20 Aug. 2018

Treatment strategies are reliant on case reports and case series with new developments in interventional treatment modalities including endoscopic therapy, radiological intervention, and surgery. Endoscopic treatment includes injection sclerotherapy using various agents, banding of varices, and clipping of varices (4). Herein we present a case of an isolated duodenal varix as the first presentation of UGIB that is rare but potentially fatal condition.

CASE REPORT

A 44-year-old woman was admitted to the hospital with a 3-day history of melena, nausea, and vomiting. The patient described similar recurrent episodes of epigastric pain, melena, nausea, and vomiting during the past 3 weeks. Two weeks before admission esophagogastroduodenoscopy (EGD) at another hospital revealed normal esophagus, portal hypertensive gastropathy without evidence of GIB in upper GI tract. Lab tests showed an inadequate response to six units of blood transfusion and the

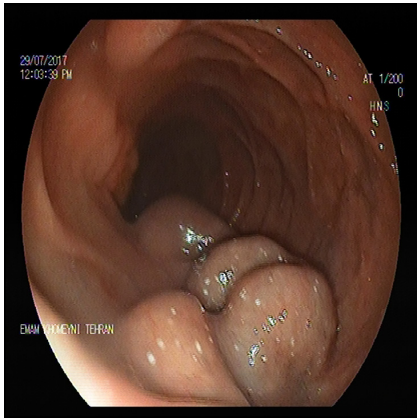


Fig.1: Duodenal varices

patient was referred to our hospital for additional examination. Vital signs on admission were: the blood pressure: 85/60 mm Hg, the oral temperature: 37.5 °C, the respiratory rate: 24 breaths per minute, and the oxygen saturation: 94% while she was breathing ambient air. General examinations were notable for 2+ lower extremity edema and there was no rigidity or tenderness at the epigastric area. Digital rectal examination confirmed the presence of melena. Laboratory tests showed: hemoglobin: 2 g/dL, white blood cell count: 9500/mm³, platelet count: 87000/mm³, sodium: 131 meq/L, potassium: 4.4 meq/L, blood urea nitrogen: 60 mg/dL, creatinine: 0.9 mg/dL, aspartate aminotransferase: 19 U/L, alanine aminotransferase: 15 U/L, serum alkaline phosphatase: 185 U/L, total serum bilirubin: 1.8 mg/dL, direct serum bilirubin: 0.7 mg/dL, serum albumin: 2.5 g/dL, serum total protein: 4.4 g/dL, and international normalized ratio: 1.21. Other electrolytes and biochemical tests were in normal ranges.

Because of her previous episode of melena, and finding anemia in the lab tests, after resuscitation with intravenous fluid, two units of packed red blood cells, and intravenous pantoprazole, esophagogastroduodenoscopy (EGD) was done. Repeat EGD revealed normal esophagus, cardia, and fundus, and snaked skin appearance in the body and antrum. The duodenum was reported to be normal. Because of concern about cirrhosis, abdominal ultrasonography was done, which showed surface nodularity and increased echogenicity of the liver, a hyperechoic mass like lesion in the left liver lobe,

and moderate splenomegaly without ascites. The patient had repeated melena and subsequent decline in the serum hemoglobin level from 6.1 to 4.2 g/dL the following morning. A contrast-enhanced CT was performed for liver mass evaluation as no prior cross-sectional imaging was available. The CT revealed a markedly cirrhotic liver, a 21×27×20 mm mass with peripheral nodular enhancement in the early phase followed by a centripetal pattern in the late phase compatible with hemangioma and previously undiagnosed multiple prominent varices involving the 3rd portion of the duodenum (figure1). A third EGD was done under conscious sedation on day 6 of her admission.

The upper GI tract was blood-free and the findings were similar to the second EGD. Additionally, there were prominent duodenal varices in the third part of the duodenum. The varix was treated successfully with cyanoacrylate glue injection. The patient subsequently remained stable and free of any further GI bleeding. Her hemoglobin level was stable at 8.7 g/dL. She was discharged from the hospital on day 10 of her admission. The patient remained well and asymptomatic of any GI bleeding one month after discharge.

DISCUSSION

UGIB is a threatening condition leading to urgent hospital admission. Hematemesis is the most frequent presenting symptom (63.5%) and peptic ulcer (duodenal ulcer in most cases) is seen as the main reason for UGIB (42.4%) in Iran (5). Sources of non-variceal bleeding include peptic ulcer disease (PUD), esophagitis, Mallory-Weiss tear, vascular anomalies, and gastric and esophageal malignancies (6).

Cirrhosis is an irreversible process of liver fibrosis and is responsible for significant morbidity and mortality worldwide. As fibrosis progresses, increased resistance to portal venous blood flow develops and portal hypertension (PHT) can occur. Complications of PHT are many, but the most threatening and acute is a variceal hemorrhage (7). Variceal bleeding is a life threatening complication of portal hypertension (8). Varices will be present in 40% of patients with clinically compensated cirrhotic liver disease. This increases to 60% when decompensated (9). The esophagus and stomach are the most common

sites for varices to develop (10). Ectopic varices are a term reserved for varices, which exist outside the esophagogastric region (3). Ectopic varices are relatively rare; however, approximately 5% are related to GIB. Ectopic varices usually occur in the rectum, duodenum, or colon, and portal hypertension is the most common cause (11). Duodenal varices account for 1-3% of all varices in patients with portal hypertension (12). Such ectopic varices are associated with an increased risk of bleeding and mortality. Not only are they a diagnostic challenge, particularly if they present as a first manifestation of portal hypertension, they are also very difficult to treat due to their location (10). Duodenal varices were first described by Alberti (13) and visualized endoscopically in 1973 by Kunisaki and colleagues (14). Endoscopic incidence of duodenal varices was found to be 0.4% in a 9-year follow-up of patients with portal hypertension (15). This discrepancy is due to the serosal and submucosal location of duodenal varices, which limits visualization during endoscopy (16). Duodenal varices can result in massive GIB, reported at around 40% mortality. Diagnosis and treatment are often difficult and controversial as experience is limited (17). Optimal management is not well established, and there are no treatment guidelines for ectopic varices. Ectopic variceal hemorrhages should be managed in the same way as gastroesophageal hemorrhages with respect to fluid resuscitation, antibiotics prescription, and octreotide with vasopressors if needed (18). Different treatment options have been utilized to control duodenal variceal bleeding including endoscopic, interventional, radiological and surgical modalities (3). Endoscopic intervention in duodenal varices can be more challenging than conventional treatment of esophageal varices. Inherent duodenal anatomy can make identifying the extent of the varix and maintaining full visualization of the lesion difficult. Furthermore, the relative thinness of the duodenal wall compared with the other parts of the upper GI tract makes this region more at risk for perforation and complications (19). Endoscopic sclerotherapy has been successfully used in the past with good outcomes, although this carries a risk of perforation. Endoscopic band ligation has also been proven successful in stopping bleeding; however, this approach is limited in varices larger than 15 mm, as

was the case with our patient, because obtaining a good view is often difficult, and isolating the feeding vessels can be problematic. Endoscopic hemoclips can be deployed and control bleeding by providing direct mechanical pressure if the afferent and efferent vessels can be isolated. Transesophageal intrahepatic portosystemic shunt (TIPS) is effective in controlling bleeding in the acute setting but has no mortality benefit over endoscopic therapies (7).

Cyanoacrylate is a tissue adhesive that rapidly polymerizes upon contact with blood and embolizes the varix. It has been used to achieve hemostasis in patients with GI variceal bleeding and specifically has been successful in primary endoscopic hemostasis or secondary therapy of duodenal varices following the failure of other endoscopic approaches (20-24). Cyanoacrylate injection is not without risks. The reported complications are pulmonary emboli, portal and splenic vein thrombosis, cerebrovascular accidents, and recurrent bleeding following cast extrusion and impaction of the injector needle within the varix (25-28). However, in our case there were no complications and the procedure was successful.

In conclusion, cyanoacrylate is a safe and effective alternative for non-TIPS candidates who present with acute duodenal variceal bleeding.

CONFLICT OF INTEREST

The authors declare no conflict of interests related to this work.

REFERENCES

1. Paudel MS, Kc S, Mandal AK, Poudyal NS, Shrestha R, Paudel BN, et al. Acute Upper Gastrointestinal Bleeding in a Tertiary Care Centre of Nepal. *JNMA J Nepal Med Assoc* 2017;56:211-6.
2. Norton ID, Andrews JC, Kamath PS. Management of ectopic varices. *Hepatology* 1998;28:1154-8.
3. Malik A, Junglee N, Khan A, Sutton J, Gasem J, Ahmed W. Duodenal varices successfully treated with cyanoacrylate injection therapy. *BMJ Case Rep* 2011:2011.
4. Farooqi AR, Sunderraj L. Modern Management of Duodenal Variceal Bleeding. *J Ayub Med Coll Abbottabad* 2017;29:340-3.
5. Minakari M, Badihian S, Jalalpour P, Sebghatollahi V. Etiology and outcome in patients with upper gastrointestinal bleeding: Study on 4747 patients in the central region of Iran. *J Gastroenterol Hepatol* 2017;32:789-96.

6. Sarin SK, Kumar A, Angus PW, Baijal SS, Chawla YK, Dhiman RK, et al. Primary prophylaxis of gastroesophageal variceal bleeding: consensus recommendations of the Asian Pacific Association for the Study of the Liver. *Hepato Int* 2008;2:429-39.
7. House T, Webb P, Baarson C. Massive Hemorrhage from Ectopic Duodenal Varices: Importance of a Multidisciplinary Approach. *Case Rep Gastroenterol* 2017;11:36-41.
8. Biecker E. Portal hypertension and gastrointestinal bleeding: diagnosis, prevention and management. *World J Gastroenterol* 2013;19:5035-50.
9. El-Tawil AM. Trends on gastrointestinal bleeding and mortality: where are we standing? *World J Gastroenterol* 2012;18:1154-8.
10. Haq I-, Shah AA, Chandramohan S. Distal Duodenal Varices: First Presentation of Upper Gastrointestinal Bleeding. *J Coll Physicians Surg Pak* 2017;27:S11-S12.
11. Hoshiai A, Tsurukiri J, Sumi Y. A rare case of obscure gastrointestinal bleeding: Small bowel varices flowing into the inferior epigastric vein. *Ulus Travma Acil Cerrahi Derg* 2017;23:266-8.
12. Sharma M, Rameshbabu CS. Collateral Pathways in Portal Hypertension. *J Clin Exp Hepatol* 2012;2:338-52.
13. Alberti W. Uberden roentgenologischen nachweis von varizen in buolbus duodeni. *Fortschro Geb Koentgenstr* 1931;43:60-5.
14. Kunisaki T, Someya N, Shimokava Y, Okuda K. Varices in the distal duodenum seen with a fiberduodenoscope. *Endoscopy* 1973;5:101-4.
15. Hashizume M, Tanoue K, Ohta M, Ueno K, Sugimachi K, Kashiwagi M, et al. Vascular anatomy of duodenal varices: angiographic and histopathological assessments. *Am J Gastroenterol* 1993;88:1942-5.
16. Sukigara M, Koyama I, Komazaki T, Matsuda T, Ishii T, Omoto R. Bleeding varices located in the second portion of the duodenum. *Jpn J Surg* 1987;17:130-5.
17. Tan NC, Ibrahim S, Tay KH. Successful management of a bleeding duodenal varix by endoscopic banding. *Singapore Med J* 2005;46:723-5.
18. Akhter N, Haskal Z. Diagnosis and management of ectopic varices. *Gastrointest Interv* 2012;1:3-10.
19. Desai RK, Tagliabue JR, Wegryn SA, Einstein DM. CT evaluation of wall thickening in the alimentary tract. *Radiographics* 1991;11:771-83.
20. Ota K, Shirai Z, Masuzaki T, Tanaka K, Higashihara H, Okazaki M, et al. Endoscopic injection sclerotherapy with n-butyl-2-cyanoacrylate for ruptured duodenal varices. *J Gastroenterol* 1998;33:550-5 .
21. Yoshida Y, Imai Y, Nishikawa M, Nakatukasa M, Kurokawa M, Shibata K, et al. Successful endoscopic injection sclerotherapy with N-butyl-2-cyanoacrylate following the recurrence of bleeding soon after endoscopic ligation for ruptured duodenal varices. *Am J Gastroenterol* 1997;92:1227-9 .
22. Onozato Y, Kakizaki S, Iizuka H, Mori K, Takizawa D, Ohyama T, et al. Ectopic varices rupture in the gastroduodenal anastomosis successfully treated with N-butyl-2-cyanoacrylate injection. *Acta Med Okayama* 2007;61:361-5 .
23. Paterlini A, Rolfi F, Buffoli F, Cesari P, Graffeo M, Benedini D, et al. Endoscopic treatment of a bleeding duodenal varix using N-butyl-2-cyanoacrylate. *Endoscopy* 1993;25:434.
24. Sato H, Fujishiro H, Rumi MA, Kinoshita Y, Niigaki M, Kohge N, et al. Successful endoscopic injection sclerotherapy for duodenal varices. *J Gastroenterol* 2002;37:143-4 .
25. Alexander S, Korman MG, Sievert W. Cyanoacrylate in the treatment of gastric varices complicated by multiple pulmonary emboli. *Intern Med J* 2006;36:462-5 .
26. Al Hamad A, Kabbani A, Al Kadhi Y. N-butyl-2-cyanoacrylate (Histoacryl) complication: a case report. *Ann Saudi Med* 2006;26:71-2.
27. Shim CS, Cho YD, Kim JO, Bong HK, Kim YS, Lee JS, et al. A case of portal and splenic vein thrombosis after Histoacryl injection therapy in gastric varices. *Endoscopy* 1996;28:461.
28. Lizardo-Sanchez L, Burdick J, Trotter JF. Safety and efficacy of 2-octyl-cyanoacrylate in the management of patients with gastric and duodenal varices who are not candidates for transjugular intrahepatic portosystemic shunts. *Proc (Bayl Univ Med Cent)* 2016;29:371-3.