

Covid-19 Presented Only with Gastrointestinal Symptoms: A Case Report of a 14-Year-Old Patient

Ladan Goshayeshi^{1,†}, Nasrin Milani^{2,†}, Robert Bergquist³, Sayyed Majid Sadrzadeh⁴,
Farnood Rajabzadeh⁵, Benyamin Hoseini^{6,7,*}

¹ Department of Gastroenterology and Hepatology, Faculty of Medicine, Mashhad University of Medical Sciences, Mashhad, Iran

² Department of Internal Medicine, Faculty of Medicine, Mashhad University of Medical Sciences, Mashhad, Iran

³ Ingerod, SE-454 94 Brastad, Sweden; Formerly UNICEF/UNDP/World Bank/WHO Special Programme for Research and Training in Tropical Diseases (TDR), World Health Organization, Geneva, Switzerland

⁴ Department of Emergency Medicine, Faculty of Medicine, Mashhad University of Medical Sciences, Mashhad, Iran

⁵ Department of Radiology, Faculty of Medicine, Islamic Azad University, Mashhad Branch, Mashhad, Iran

⁶ Department of Health Information Technology, Neyshabur University of Medical Sciences, Neyshabur, Iran

⁷ Pharmaceutical Research Center, Mashhad University of Medical Sciences, Mashhad, Iran

† These two authors contributed equally to this paper

ABSTRACT

Coronavirus disease 2019 (Covid-19) is expanding worldwide. Although it seems to be a purely respiratory disease, occasional reports of lesions in other organs have been published. We report here an asymptomatic child with Covid-19 and with the main symptom of abdominal pain distension and without any respiratory symptoms.

A 14-year-old male patient with main complaints of fever, malaise, anorexia, and severe abdominal pain was admitted to a hospital in Mashhad, Iran. Laparotomy revealed distension of the small intestine and an adhesive ileocaecal band that had produced ileum herniation without free fluid in the abdomen. Chest radiography and high-resolution computed tomography of the lungs showed bilateral and diffuse, peripheral dense areas of ground-glass appearance. A nasopharyngeal swab for diagnosis of Covid-19, was ordered due to lymphopenia together with these diffuse lung infiltrations, which showed a positive result. This led to drug treatment with lopinavir/ritonavir, hydroxychloroquine, ribavirin/oseltamivir, and meropenem. The patient was febrile and developed tachycardia on the third day, accompanied by a respiratory rate of 44/min. At this point, tracheal intubation was done, but the patient died after 3 hours due to cardiac arrest. The case report brings forth the hypothesis that the gastrointestinal manifestation may be an atypical symptom of Covid-19 infection and highlights the importance of the diagnosis based on combined laboratory-based data and scanning imagery.

Keywords: COVID-19, Gastrointestinal symptoms, Case report, Abdominal pain, Acute respiratory disease

please cite this paper as:

Goshayeshi L, Milani N, Bergquist R, Sadrzadeh SM, Rajabzadeh F, Hoseini B. Covid-19 Presented Only with Gastrointestinal Symptoms: A Case Report of a 14-Year-Old Patient. *Govaresh* 2021;25:300-304.

*Corresponding author:

Benyamin Hoseini, PhD by Research
Department of Health Information Technology,
Neyshabur University of Medical Sciences, Neyshabur,
Iran Pharmaceutical Research Center, Mashhad
University of Medical Sciences, Mashhad, Iran;
Tel: + 98 51 43306219
Fax: + 98 51 43306219
Email: Hoseinib1@nums.ac.ir.

Received: 17 May 2020

Edited: 04 Oct. 2020

Accepted: 05 Oct. 2020

INTRODUCTION

In December 2019, the coronavirus disease 2019 (Covid-19), caused by the severe acute respiratory syndrome coronavirus 2 (SARS-CoV-2), was emerged in China and is currently spreading worldwide. Although it seems to be a purely respiratory disease, occasional reports of lesions in other organs have been published (1-3). The most common symptoms of Covid-19 are fever, dry cough, and often breathing difficulties, while other manifestations are uncommon (1,2). Intestinal presentations observed with the severe acute respiratory syndrome (SARS) were also uncommon,

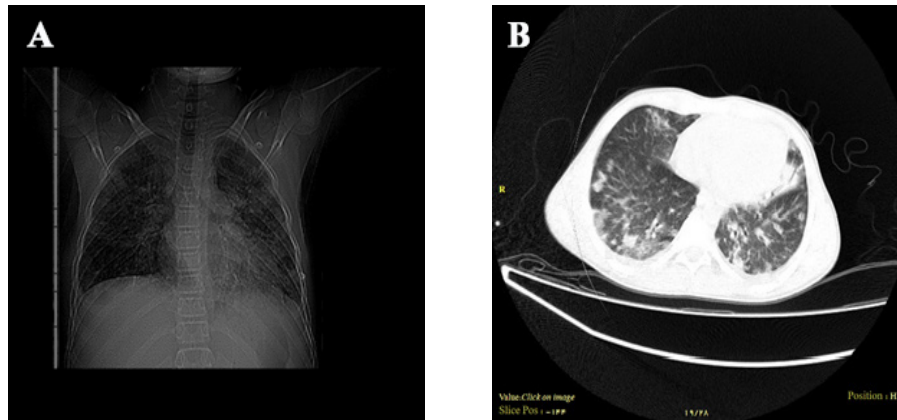


Fig.1: A): Chest radiograph and B) high-resolution computed tomogram of the lung of the presented case in the study.

although two of six cases reported by Chan and colleagues had diarrhea (4). Other researchers have found microvascular injuries and thrombosis in various parts of the body (3). Sharing clinical data and experience may contribute to the control of emerging infectious diseases (5). Here we report a 14-year-old boy with Covid-19 without respiratory symptoms, suffering only from abdominal pain and fever.

CASE REPORT

On March 6, 2020, a 14-year-old boy with main complaints of fever, malaise, anorexia, severe abdominal distension, and pain was admitted to the Hasheminejad Hospital in Mashhad, Iran. He had no respiratory complaints such as cough, rhinorrhea, sore throat, chest discomfort, or dyspnoea. The physical examination showed a body temperature of 39°C, blood pressure: 100/70 mm Hg, heart rate: 95 beats/min, and a respiratory rate of 20 breaths/min. Abdominal inspection revealed tenderness in the right lower quadrant with severe distension together with generalized abdominal tenderness. Although he reported no underlying medical conditions or surgery, severe abdominal pain with cramps in the epigastric and peri-umbilical areas had occurred three days before admission, together with abdominal distension and constipation.

Laboratory tests on the first day of admission revealed leukocytosis (14,000/mm³ with 12,200 [87%] polymorphonuclear cells), a platelet count of 253,000/μL, a hemoglobin level of 13.8 g/dL, a C-reactive protein of 75 mg/L, and the normal liver

function tests (amylase and lipase). Further, the sedimentation rate was 10 mm.

Due to suspicion of so-called acute abdomen, including appendicitis, the patient was directly referred to the operating room upon admission. Laparotomy revealed distension of the small intestine and an adhesive ileocaecal band that was surgically removed as it had produced ileum herniation. There was no free fluid in the abdomen, and the patient was referred to the recovery room.

In the recovery room, the pulse rate of 140 and respiratory rate of 36-40 per min with a saturated O₂ of 86% led to a referral to the intensive care unit (ICU). Chest radiography (CXR) and high resolution computed tomography (HRCT) of the lungs were performed (Fig.1 A, B), which showed bilateral, diffuse, peripheral dense areas of ground-glass appearance. On the second day after admission, the temperature was 38.6°C, the pulse rate was 120/min, the respiratory rate was 36/min, and the saturated O₂ was 81%. The laboratory report revealed a platelet count of 50,000/μL and leukopenia with a white cell count of 2,000/mm³ (55% neutrophils and 40% lymphocytes). Laboratory data for this case was demonstrated in table 1.

Because of the lymphopenia together with diffuse lung infiltration against the background of the currently ongoing Covid-19 pandemic, a nasopharyngeal swab for Covid-19 diagnosis was ordered, and the result was positive based on real-time reverse-transcriptase polymerase chain reaction (rRT-PCR). This led to drug treatment with lopinavir/ritonavir,

Table 1: Laboratory data related to the presented case

Variables	Attendance at emergency	First day of admission	Second day of admission
Urea (mg/dL)		73	83
Creatinine (mg/dL)		1.5	1.4
Sodium (mg/dL)			129
Potassium (mg/dL)			5.3
WBC (1000/microL)	14000		2000
Hemoglobin (g/dL)	13.8		15.3
MCV (fL)	82		81.5
MCH (pg)	29.1		28
MCHC (g/dL)	35		34.3
PLT (ng/mL)	253000		50000
Neutrophils (%)	87%(12200)		55%
Lymphocyte (%)	4.2%(600)		40%
Monocyte			2%
Eosinophil			3%
ESR (mm)	10		
CRP (Iu/mL)	+		
PH			7.198
Hco ₃ (mmol/dL)			12
Pco ₂ (mm Hg)			25
Po ₂ (mm Hg)			30
O ₂ sat.			48

WBC: White blood cell, MCV: Mean corpuscular volume, MCH: Mean corpuscular hemoglobin, ESR: Erythrocyte sedimentation rate, CRP: C-reactive protein.

hydroxychloroquine, ribavirin/oseltamivir, and meropenem. The patient remained febrile on the third day and developed tachycardia with a pulse rate of 170/min. The blood pressure fell to 70/50 mm Hg, accompanied by a respiratory rate of 44/min. At this point, tracheal intubation was done, but the patient died after 3 hours due to cardiac arrest. After one week, the surgeon who had operated on the patient became febrile, and his Covid-19 test was positive as well, so treatment, as described above was started, and he made a rapid recovery.

DISCUSSION

Unknown aspects of Covid-19 infection not only make the disease difficult to prevent but also enable it to persist until large numbers of people either die or recover (6). This case report of a 14-year-old boy with non-respiratory symptoms highlights the importance of also addressing currently uncommon symptoms such as gastrointestinal symptoms as possible manifestations of Covid-19. In this case, the main

symptom was abdominal pain and distension without any respiratory symptoms; however, HCRT of the lung revealed diffuse infiltrations bringing forth the hypothesis that gastrointestinal manifestations might have been atypical symptoms of Covid-19 infection.

Ungaro and colleagues 7 noted that patients with Covid-19 infection might complain of gastrointestinal symptoms, such as nausea or diarrhea, similar to that noted during the SARS outbreak (4). In fact, diarrhea was one of the most prominent symptoms in the first U.S. case of Covid-19, and the novel SARS-CoV-2 coronavirus was then detected in patient's stool (8). In this case, the gastrointestinal symptoms were those of ileus and intestinal obstruction that may have been caused by Covid-19. Naturally, the two different diseases might have been coincidental.

The most common cause of bowel obstruction in young children includes postoperative adhesions, intussusception, hernia, Meckel's diverticulum, all of which may require prompt surgical intervention (9). Some of these aetiologies are related to viruses,

such as intussusception during early childhood, while viral gastroenteritis due to sapovirus can lead to intestinal obstruction and present with severe abdominal distension and vomiting in children (10). Other viruses, such as rotavirus or norovirus, can affect the enteric nervous system along with increased luminal contents from malabsorption and lead to severe intestinal distension (11). In our case, the Covid-19 infection was confirmed, and the severe intestinal distension may be a presentation of Covid-19 infection. Alternatively, the presence of an adhesion band could have been coincidental with a primarily asymptomatic Covid-19 respiratory infection.

Although fever and cough are the dominant symptoms of Covid-19, and gastrointestinal symptoms are uncommon (12), digestive symptoms are indeed common in patients with Covid-19 (13), and there have been multiple reports to date of children with asymptomatic Covid-19 infection (14). The microvascular injuries in different parts of the body during the Covid-19 infection reported by Magro and co-workers (3) could also have played a role here. It is thus suggested that digestive symptoms, such as diarrhea, should not only be thought of as a possibility, but this suspicion should immediately be raised in at-risk patients presenting with digestive symptoms. However, we report only one case, and a common gastrointestinal involvement cannot be concluded at this point in time. To confirm these findings and make the findings generalized, a large-sample study with emphasis on abdominal symptoms is needed.

HRCT examination plays an important role in the initial diagnosis of Covid-19 pneumonia as it shows typical imagery. The demonstration of multiple, bilateral ground-glass opacities in a patchy pattern with multiple lobular peripheral distributions are typical features of Covid-19 pneumonia (15). In our study, HRCT of the lungs revealed infiltrations that aided the diagnosis when accompanied by laboratory data such as lymphopenia and high C-reactive protein readings.

We report the clinical characteristics of an asymptomatic boy with Covid-19 in Iran and highlight the non-specific nature of clinical presentations and the importance of the diagnosis to be based on combined laboratory-based data and scanning imagery.

Declarations

Ethical approval. This study was approved by the

Research Ethics Committee of Mashhad University of Medical Sciences that means this patient could only be described in this study and should not be reported by anyone else, and any new reporting on this case needs to get new approval of this Committee.

Consent for publication. Because the patient died, the written informed consent was obtained from his father for publication of this case report and any accompanying images. A copy of the written consent is available for review by the Editor of this journal.

Availability of data and materials. All data will be available upon request by permission of the corresponding author and Research Ethics Committee of Mashhad University of Medical Sciences.

Competing interests. The authors declare that they have no competing interests.

Authors' contributions. NM, and SMS gathered the patient's data. LG, BH, and NM interpreted the patient's data regarding the clinical aspect. FR interpreted the patient data regarding the radiological aspect. LG, BH, and RB were the major contributors in writing the manuscript. All authors read and approved the final manuscript.

ACKNOWLEDGMENTS

Not applicable.

Funding:

This study received no funding.

CONFLICT OF INTEREST

The authors declare no conflict of interests related to this work.

REFERENCES

1. Huang C, Wang Y, Li X, Ren L, Zhao J, Hu Y, et al. Clinical features of patients infected with 2019 novel coronavirus in Wuhan, China. *Lancet* 2020;395:497-506.
2. Goshayeshi L, Akbari Rad M, Bergquist R, Allahyari A, Hoseini B. Demographic and Clinical Characteristics of the Severe Covid-19 Infections: First Report from Mashhad University of Medical Sciences, Iran. *Med Rxiv* 2020:2020.05.20.20108068.
3. Magro C, Mulvey JJ, Berlin D, Nuovo G, Salvatore S, Harp J, et al. Complement associated microvascular injury and thrombosis in the pathogenesis of severe COVID-19 infection: a report of five cases. *Transl Res* 2020;220:1-13.

4. Chan JF-W, Yuan S, Kok K-H, Kai-Wang To K, Chu H, Yang J, et al. A familial cluster of pneumonia associated with the 2019 novel coronavirus indicating person-to-person transmission: a study of a family cluster. *Lancet* 2020;395: 514-23.
5. Lu S, Lin J, Zhang Z, Xiao L, Jiang Z, Chen J, et al. Alert for non-respiratory symptoms of Coronavirus Disease 2019 (COVID-19) patients in epidemic period: A case report of familial cluster with three asymptomatic COVID-19 patients. *J Med Virol* 2020.
6. Bergquist R, Rinaldi aL. Covid-19: Pandemonium in our time. *Geospat Health* 2020;15.
7. Ungaro RC, Sullivan T, Colombel JF, Patel G. What Should Gastroenterologists and Patients Know About COVID-19? *Clin Gastroenterol Hepatol* 2020;18:1409-11.
8. Holshue ML, DeBolt C, Lindquist S, Lofy KH, Wiesman J, Bruce H, et al. First Case of 2019 Novel Coronavirus in the United States. *N Engl J Med* 2020;382:929-36.
9. Ambartsumyan L, Rodriguez L. Gastrointestinal motility disorders in children. *Gastroenterol Hepatol (N Y)* 2014;10:26-16.
10. Model L, Burnweit CA. Sapovirus Gastroenteritis in Young Children Presenting as Distal Small Bowel Obstruction: A Report of 2 Cases and Literature Review. *Case Rep surg* 2016; 2016:6302875.
11. Navaneethan U, Giannella RA. Mechanisms of infectious diarrhea. *Nat Clin Pract Gastroenterol Hepatol* 2008;5:637-47.
12. Guan WJ, Ni ZY, Hu Y, Liang WH, Ou CQ, He JX, et al. Clinical characteristics of coronavirus disease 2019 in China. *N Engl J Med* 2020;382:1708-20.
13. Pan L, Mu M, Yang P, Sun Y, Wang R, Yan J, et al. Clinical Characteristics of COVID-19 Patients With Digestive Symptoms in Hubei, China: A Descriptive, Cross-Sectional, Multicenter Study. *Am J Gastroenterol* 2020;115:766-73.
14. Zhao D, Yao F, Wang L, Zheng L, Gao Y, Ye J, et al. A comparative study on the clinical features of COVID-19 pneumonia to other pneumonias. *Clin Infect Dis* 2020;71:756-61.
15. Xu X, Yu C, Qu J, Zhang L, Jiang S, Huang D, et al. Imaging and clinical features of patients with 2019 novel coronavirus SARS-CoV-2. *Eur J Nucl Med Mol Imaging* 2020;47:1275-80.