

Sigmoidal Endometrioma; a Rare Subepithelial Lesion Mimicking Gastrointestinal Stromal Tumors: A Case Report

Pouyan Ebrahimi¹, Seyed Farhad Tayari², Ahmad Hormati^{3,4}, Sajjad Ahmadpour³, Seyed Hassan Abedi^{5*}

¹Student Committee Research, Babol University of Medical Science, Babol, Iran

²Colorectal Research Center, Shiraz University of Medical Sciences, Shiraz, Iran

³Gastroenterology and Hepatology Diseases Research Center, Qom University of Medical Sciences, Qom, Iran

⁴Assistant Professor of Gastroenterology and Hepatology, Department of Internal Medicine, School of Medicine, Gastrointestinal and Liver Diseases Research Center, Colorectal Research Center, Hazrat-e Rasool General Hospital, Iran University of Medical Sciences, Tehran, Iran

⁵Assistant Professor of Gastroenterology and Hepatology, Cancer Research Center, Health Research Institute, Babol University of Medical Sciences, Babol, Iran

ABSTRACT

The ectopic endometrial tissue can be found in different places with no symptoms (such as intestinal endometriosis) and common symptoms such as abnormal bleeding, dysmenorrhea, and chronic pelvic pain. Early diagnosis and treatments, especially with surgical procedures, play an important role in patients' recovery.

We describe a 39-year-old woman with intermural and submucosal endometriosis. The compressive effect of the mass in the rectosigmoid colon caused digestive symptoms. After necessary procedures such as colonoscopy, computed tomography (CT) and endoscopic ultrasonography (EUS), we performed surgery, and the distal colon was resected.

Ovarian cysts caused by endometrial tissue displacement can have symptoms similar to gastrointestinal stromal tumors (GISTs) if they are large enough to push through the gastrointestinal (GI) system. These symptoms can be diarrhea, abdominal tenderness, and so on. Surgery is the best diagnostic way for endometriomas and one of the diagnostic ways in GISTs. Also, with considering the drug resistance of GISTs to the current chemotherapy, the best treatment is also surgery.

Location and tissue involvement of masses of the GI system are important points that should be considered in the differential diagnoses. In this way, early diagnosis and timely treatment, especially surgical, will have the best prognosis for the affected patients.

Keywords: Sigmoidal Endometrioma; Subepithelial Lesion ; Gastrointestinal; Stromal; Tumors

Please cite this paper as:

Ebrahimi P, Tayari SF, Hormati A, Ahmadpour S, Abedi SH. Sigmoidal endometrioma; a rare subepithelial lesion mimicking gastrointestinal stromal tumors: a case report. *Govareh* 2022;27:55-59.

*Corresponding author:

Seyed Hassan Abedi, MD

Cancer Research Center, Health Research Institute,
Babol University of Medical Sciences, Babol, Iran

Tel: + 98 11 32288891

Fax: + 98 11 32288891

Email: h.abedi@mubabol.ac.ir

Received :04 Jul. 2021

Edited : 15 Dec. 2021

Accepted: 16 Dec. 2021

INTRODUCTION

The implantation of endometrial tissue as ectopic tissue outside of the uterus is called endometriosis. This ectopic tissue can be placed not only in different parts of the

pelvic cavity, such as ovaries and uterine ligaments, but also in the abdominal cavity or even in the lung by the return of endometrial cells during menstrual bleeding and peritoneal binding at the abdominal cavity (1-3). Therefore, a different range of symptoms can occur due to its location, from no symptom (such as intestinal endometriosis) to common symptoms such as abnormal bleeding, dysmenorrhea, chronic pelvic pain and so on (4,5). Timely diagnosis and surgical treatment can be the best solution for these patients (1). Gastrointestinal mesenchymal tumors can be referred to as gastrointestinal stromal tumors (GIST), which originate from Cajal cells, and considering that in 10% of cases are found only during surgery, this can simply be confused with other diagnoses (6).

CASE REPORT

A 39-year-old nulliparous woman was referred to us for endoscopic ultrasonography (EUS). Migraine and fibroid surgery were in the patient's medical history, and she was under treatment with clonazepam, propranolol, and nortriptyline for a psychological disease. She had metrorrhagia for a long time. Two months earlier, she was treated with metronidazole due to severe fever and chills and had a weight loss of 10 kg. Three weeks earlier, she was admitted to the hospital because of bloody diarrhea and abdominal pain during defecation. Then she underwent colonoscopy and abdominal radiography before and after contrast injection. In the colonoscopy report, the scope could not pass from sigmoid-descending junction, and in addition to the erythema and external hemorrhoids, decreased vascularity and aphthous lesion with a large mass were observed in that place. So, two biopsy specimens were taken, and computed tomography (CT) was ordered (Figure 1). In pathological response, there were unremarkable colon mucosa and active focal colitis with focal few atypical cells that did not fulfill the criteria for dysplasia. The spiral abdominal and pelvic CT with intravenous (IV) and oral contrasts reported a 16 mm accessory spleen in the splenic hilum plus a 33 mm cyst in the left ovary (Figure 2).

According to the findings and normal vital signs as well as her weight loss, we noticed left inguinal tenderness on her examination. To rule out a sigmoidal cyst, we did EUS, and in colonoscopic view, we saw a subepithelial lesion on 25 cm of anal verge in the sigmoid. There were few ulcerations on the mass, and the scope did not pass due to stenosis. In EUS study, there was a 23×17 mm hypoechoic homogenous lesion originating from muscularis mucosa. Regional lymph nodes were not found (Figures 3,4). Finally, we diagnosed a subepithelial lesion suggestive for GIST and recommended surgeon consultation. To better diagnosis, we injected methylene blue around the lesion and, performed colonoscopy using colonoscopic tattooing technique.

During the surgery, several adhesions in that area obliged the surgeon to have a double j stent and open surgery. Subsequently, a distal part of the colon 15 cm in length and 4.5 cm in maximum diameter was resected along with the surrounding fat tissue. On external examination,

there was a luminal narrowing area with colon wall firmness measuring 4×3 cm, 6 cm away from proximal margin and 5.5 cm away from the distal margin, which after opening it, a broad-based endophytic polypoid mass measuring 4.1×3×1.7 cm with partial luminal obstruction and intact mucosal surface were seen. Also, a small firm nodular mass measuring 0.5 cm in diameter was seen in the submucosa of the colon wall near the distal margin (Figure 5). In the pathological examination of the upper part of the rectum and sigmoid samples, intermural and submucosal endometriosis with no sign of malignancy was reported (Figure 6). The patient was discharged with a good general appearance and normal condition and recommended to follow up after 6 months with colonoscopy. In the follow-up visit, the general condition of the patient was good and normal colon with surgical scar and no previous conflicts were seen.

DISCUSSION

Chocolate cysts (endometrioma) include less than half of benign ovarian cysts with a higher prevalence in East Asia (1,7). These cysts are nearly seven times more in infertile women than fertile women (7). Endometrioma is one of the three clinical forms of endometriosis (other forms including DIE or DEEP infiltrating endometriosis and peritoneal endometriosis) (2). These cysts are usually formed in the left ovary and in its ceiling, and given that endometrial tissues are more inclined to the right of the inguinal area (in terms of the difference in the location of this tissue), these orientations may be related to regional anatomy and preventive effect of sigmoid and intraepithelial flow (1, 3). One of the theories that explain this condition is that the formation of endometrioma can be the result of the metaplasia of the invaginated ovarian epithelium, and due to follicular fluid, endometrial cells can grow and implant on the surface of the ovary, and by infiltration of ectopic cells, the destruction begins (1). These low echo cysts are actually fibrous capsules containing blood (5). Early age at menarche, dysmenorrhea, shorter and regular periods, low body weight, tall height, and alcohol and caffeine consumption increase the risk of endometrioma and regular smoking, routine exercise and multiparity are some of the reasons for reducing the risk of endometrioma (7). Our nulliparous patient had irregular periods for a long

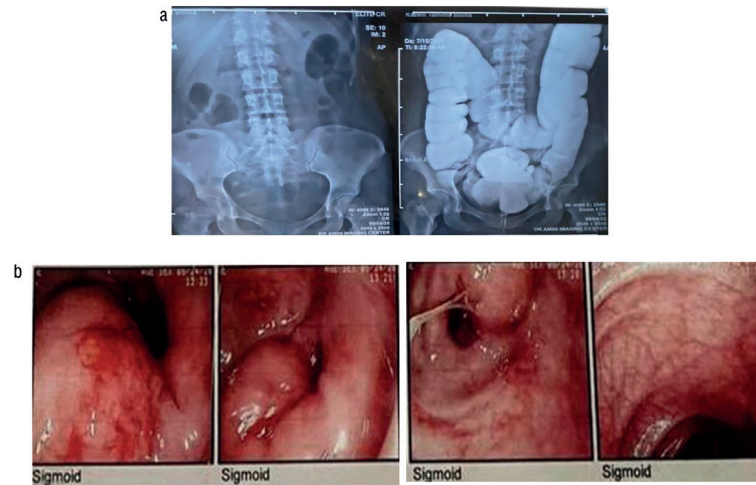


Fig. 1: a. abdominal radiographs before and after using contrast b. an aphthous lesion with a large mass plus decreased vascularity were observed in the sigmoidal area

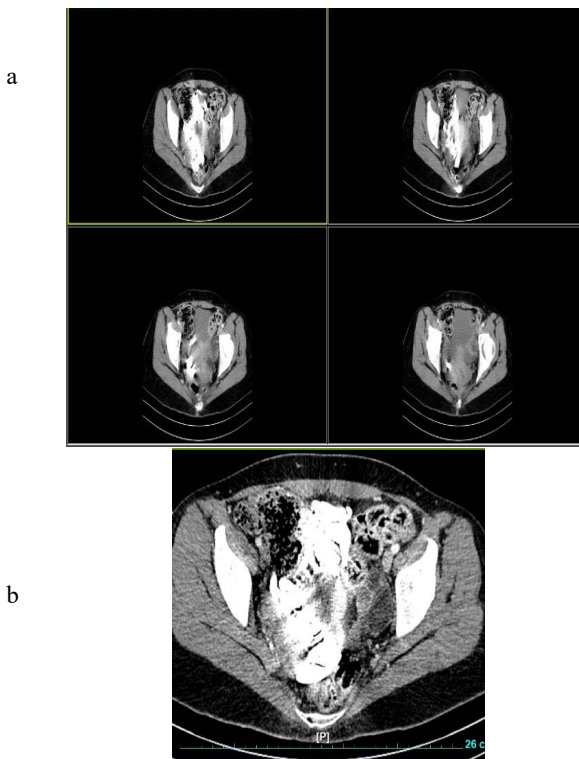


Fig. 2: a & b. a 33-mm cyst in the left ovary in the spiral abdominal and pelvic tomograms with intravenous and oral contrasts

time, and she had normal body weight and height with no family history and no alcohol and caffeine consumption. She was not a smoker and worked out occasionally. Intestinal endometriosis is usually asymptomatic, but the presentation can be with diarrhea, constipation, nausea,

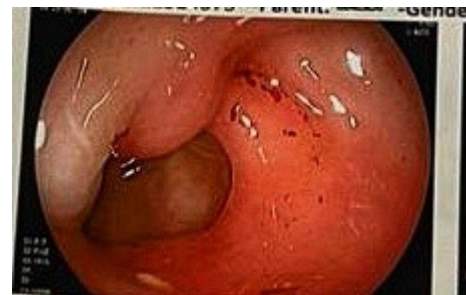

Fig.3: A mass with a few ulcerations on 25 cm of anal verge in the sigmoid

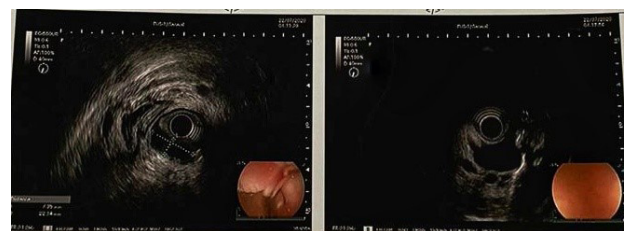

Fig. 4: A 23x17 mm lesion in EUS

vomiting, bleeding, and pelvic pain (4). These symptoms alone have many differential diagnoses, including the tumors of the gastrointestinal system that can cover a large number of them.

GISTs are the most common mesenchymal tumor of the GI, and Cajal intestinal cells are the precursor to these tumors (1, 6). They are presented in 55-65-year-old people, and their prevalence is less than 1% of GI

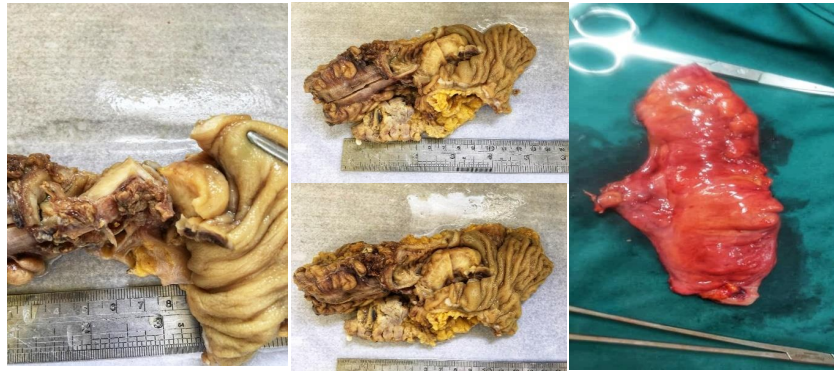

Fig. 5: Mass sizes and external view

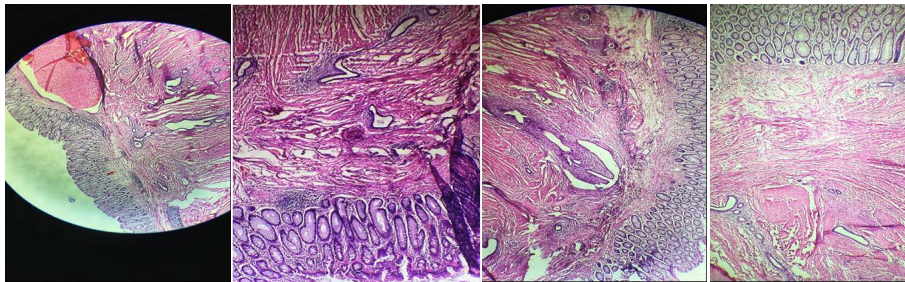


Fig. 6: Pathological aspects

tumors (6). These tumors are located anywhere in the digestive system, such as the omentum, mesentery, or retroperitoneum, but they are most common in the stomach and have a better prognosis than other sarcomas (8,9). These tumors have a pattern of exophytic growth and less lymph node involvement than other intestinal tumors such as carcinoids or lymphoma and so on. from the expression of the gene and growth factors, they have differences with other mesenchymal tumors, such as schwannoma or lymphoma (6,8). Symptoms of GISTs can include bleeding (the most important symptom either in the form of melena or hematemesis), abdominal pain, abdominal distension, and common symptoms like nausea and vomiting, early satiety, and weight loss. Considering that GISTs are asymptomatic in 20% of the cases, they can be missed easily (6). Our patient had GISTs like symptoms, including bloody diarrhea, weight loss, abdominal tenderness, and pain during defecation, but according to the age factor, it needed further investigation.

The gold standard of diagnosis of endometrioma is laparoscopy (1). Magnetic resonance imaging (MRI) with

high sensitivity and specificity, CT, ultrasonography, and transvaginal ultrasonography can also be helpful in the diagnosis, but biopsies of suspected tissue and pathological investigations provide a definitive diagnosis (10). CT, MRI, and according to the conditions, colonoscopy are diagnostic tools for GISTs. Recently EUS also provided a worthwhile position in the diagnosis of subepithelial lesions. Based on limited information from EUS of these lesions in the lower part of the GI system, the GISTs are lesions with low echogenicity and in continuity with muscularis propria (11). In our patient, colonoscopy and CT were performed, and EUS showed hypoechoic lesion, but we could not reach the main diagnosis without surgery. In the treatment of endometrioma, in addition to symptoms control, we aim to prevent the progression of the disease. Medications including non-steroidal anti-inflammatory drugs, oral contraceptive pill, progestin, and Gonadotropin-releasing hormone can be used to control symptoms, but without surgery, this treatment is not effective. Laparoscopy is usually done for cysts larger than 3cm before in vitro fertilization or generally for

masses larger than 4 cm. possibility of recurrence of these cysts exists after surgery, and it is about 12-30% after 2-4 years in adults since the first surgery (1). Given that GISTs are resistant to chemotherapy, early diagnosis and timely surgery is the best treatment option. Tyrosine kinase inhibitors are also introduced in the treatment of these tumors, but like endometrioma, surgery resulted the best treatment outcomes (6). The presence of hypoechogenic, irregular, homogeneous, or heterogeneous lesions around or infiltrating pelvic structures or the intestinal wall are considered suspect of endometriosis (12).

CONCLUSION

Endometrioma is easily confused with other digestive diagnoses such as GISTs in case of intestinal symptoms. In women aged 15 to 49 years, gynecological problems including endometriosis, should be considered as one of the differential diagnoses. Since surgery is considered as the first line in the treatment of GISTs and provides the most important clues for the diagnosis of endometrioma, then it can be noted that timely surgery is our best option for these patients. The interesting thing about this case was the location (distal colon) and the intestinal and obstructive signs that the cyst had created. In EUS pattern, endometriosis may be seen as having a hypoechoic pattern at submucosalpropria, which falls into the differential diagnosis with GIST. Therefore, the differential diagnoses must be considered in women of reproductive age, especially if they have clinical symptoms of endometriosis (13).

ETHICS APPROVAL:

The study protocol was approved by the Ethics Committee of Babol University of Medical Sciences (ethical code: IR.MUBABOL.REC.1400.101).

CONSENT FOR PUBLICATION:

Not applicable.

AVAILABILITY OF DATA AND MATERIAL:

All data and images are available from the corresponding author.

FUNDING:

This work was not supported financially by any institution.

CONFLICT OF INTEREST

Authors declare that they have no conflict of interest.

REFERENCES:

1. Gałczyński K, Józwiak M, Lewkowicz D, Semczuk-Sikora A, Semczuk AJJoor. Ovarian endometrioma—a possible finding in adolescent girls and young women: a mini-review. *J Ovarian Res* 2019;12(1):1-8.
2. Erol T, Reis E, Koç Ö, Taşbaş BJTjos. Colon resection for endometriosis. *Turk J Surg* 2019; 35(4):325-328.
3. Honl R, Karmy-Jones RJJfVU. Noninvasive Duplex Ultrasound Findings of Left-Sided Inguinal Endometriomas. *J Vasc Ultrasound* 2019;43(1):34-7.
4. Kafadar MT, Çaviş T, Sürgit Ö, Köktener A. Endometriosis of rectosigmoid colon mimicking gastrointestinal stromal tumor. *Turk J Surg* 2018;36(4): 409–12.
5. Collins BG, Ankola A, Gola S, McGillen KLJR. Transvaginal US of endometriosis: looking beyond the endometrioma with a dedicated protocol. *Radiographics* 2019;39(5):1549-68.
6. Dziadkowiec KN, Stawinski P, Sánchez-Luna SA, Katz AJC. Gastrointestinal Stromal Tumor (GIST) Causing Obscure Gastrointestinal Bleeding: An Uncommon Way of Diagnosing An Uncommon Disease. *Cureus* 2020;12(8):
7. Rehmer JM, Flyckt RL, Goodman LR, Falcone TJO, Survey G. Management of Endometriomas. *Minerva Ginec* 2019;74(4):232-40.
8. Dayan E, Zhu H, Copperman AB, Lewis S, Kamath AJCI. Gastrointestinal stromal tumor presenting as a right adnexal mass with histopathologic correlation. *Clin Imaging* 2017;44:97-100.
9. Farag A, Ezzeldin M, Mosalam N, Mohammed MJQAIJoM. Retrospective Analysis of Clinical Epidemiology in Gastrointestinal Stromal Tumour. *Int J Med* 2020;113, Issue Supplement_1,
10. Kanthimathinathan V, Elakkary E, Bleibel W, Kuwajerwala N, Conjeevaram S, Tootla FJDD, et al. Endometrioma of the large bowel. *Dig Dis Sci* 2007;52(3):767-9.
11. Cazacu IM, Singh BS, Chavez AAL, Koduru P, Ejaz S, Weston BR, et al. EUS and EUS-guided FNA/core biopsies in the evaluation of subepithelial lesions of the lower gastrointestinal tract: 10-year experience. *Endosc Ultrasound* 2020;9(5):329.
12. Rossini LGB, Drigo JM, Leite GdFC. Endoscopic Ultrasound and Intestinal Endometriosis. *Endoscopic Ultrasound-From Usual to Special*. Intech Open; 2017.
13. Wadhwa V, Slattery E, Garud S, Sethi S, Wang H, Poylin VY, et al. Endometriosis mimicking colonic stromal tumor. *Gastroenterol Rep* 2016;4(3):257-9. a