

Causal Association between Isotretinoin and Inflammatory Bowel Disease: A Case Report

Daryani NE¹, Taba Taba Vakili S², Fereshtehnejad SM³, Afshariyan S⁴

¹ Department of Gastroenterology, Imam Khomeini Hospital, Tehran University of Medical Sciences, Tehran, Iran

² Resident of Internal Medicine, Shahid Beheshti University of Medical Sciences (SBMU), Tehran, Iran

³ Clinical Research Development Center (FCRDC), Gastrointestinal and Liver Disease Research Center (GILDRC), Tehran University of Medical Sciences, Tehran, Iran

⁴ Researcher, Tehran University of Medical Sciences, Tehran, Iran

ABSTRACT

Roaccutane® (isotretinoin) is used for the treatment of severe forms of acne resistant to adequate standard therapy. Inflammatory bowel disease (IBD) is described as a possible adverse drug reaction in the product information of isotretinoin.

In a case study, we report the case of a 30 year old woman with a history of bloody diarrhea, abdominal pain and severe folliculitis/acne which had been treated with isotretinoin. Her clinical features worsened whilst on isotretinoin. Colonoscopy demonstrated diffuse ulcerative pancolitis. Isotretinoin treatment was discontinued and the patient was prescribed 5-aminosalicylic acid and corticosteroids. After a few months, steroids were discontinued and the patient went into clinical and laboratory remission. Evaluation of the possible causal association between isotretinoin treatment and IBD suggested a probable relationship, which should lead to considerable caution while prescribing this drug.

Keywords: Isotretinoin ; Acne ; Inflammatory bowel disease ; Ulcerative colitis

Govareh/ Vol. 16, No.1, Spring 2011; 68-71

INTRODUCTION

Roaccutane® (isotretinoin) is used for the treatment of severe forms of acne that are resistant to adequate standard therapy with systemic antibiotics and topical treatment (1). Isotretinoin affects the skin by decreasing sebum production and normalizing increased skin shedding (2). It has been shown to exhibit diverse effects on epithelial cell turnover, as well as glycoprotein and cytokine synthesis. More recently,

advances in our understanding of the immunology of the gut have shown a fundamental role for retinoids in the regulation of the intestinal mucosal immune response. Sometimes abnormalities, include Crohn's disease and ulcerative colitis, may not appear until months to a year or more after the discontinuation of isotretinoin (3).

In the product information of isotretinoin it is stated that gastrointestinal adverse drug reactions occur with a chance of less than 1/10,000. Furthermore, in the section 'Special warnings and precautions for use' inflammatory bowel disease (IBD) has been associated with isotretinoin therapy in patients with no prior history of intestinal disorders. Although IBD is described as a possible adverse drug reaction in the product information of isotretinoin, this association has been given little attention in the literature (2).

IBD has not been noted in clinical trials of isotretinoin in the treatment of acne, but the exposure length and number of patients in trials may not have been sufficient. The association has been documented only

Corresponding author:

Department of Gastroenterology, Imam Khomeini Hospital, Tehran University of Medical Sciences, Tehran, Iran

Tel: + 98 2188799446

Fax: + 98 2188799840

Email: nebrahim@sina.tums.ac.ir

Received : 4 Apr. 2011

Edited : 10 May 2011

Accepted : 12 May 2011

in case reports/series and in analysis of post-marketing safety data. With this case report we attract physicians' awareness to this alleged association.

CASE REPORT:

A 30 year old woman presented to our private clinic with a 24 week history of bloody diarrhea accompanied by abdominal pain relieved by defecation and tenesmus. The patient denied weight loss, fever, vomiting, skin rashes, arthralgias or vision disturbances. She had not traveled and had no exposure to sick people or animals. She had no risk factors for sexually transmitted diseases and no family history of chronic disease. The patient's medical history was remarkable for severe folliculitis/acne diagnosed 3 months earlier that was treated with isotretinoin twice daily for 40 days. Blood tests revealed normocytic anemia with hemoglobin of 9.7 g/dl, erythrocyte sedimentation rate (ESR) was 100 mm/hour and C-reactive protein was 156 mg/L. Infectious causes were ruled out by negative stool cultures for bacteria and parasites. Serum viral markers were all negative. Colonoscopy demonstrated diffuse ulcerative pancolitis. (Figure 1). Histological examination of mucosal biopsies taken during colonoscopy revealed severe, chronic, active, crypt-destructive colitis. No dysplasia was seen. Also due to an elevated serum alkaline

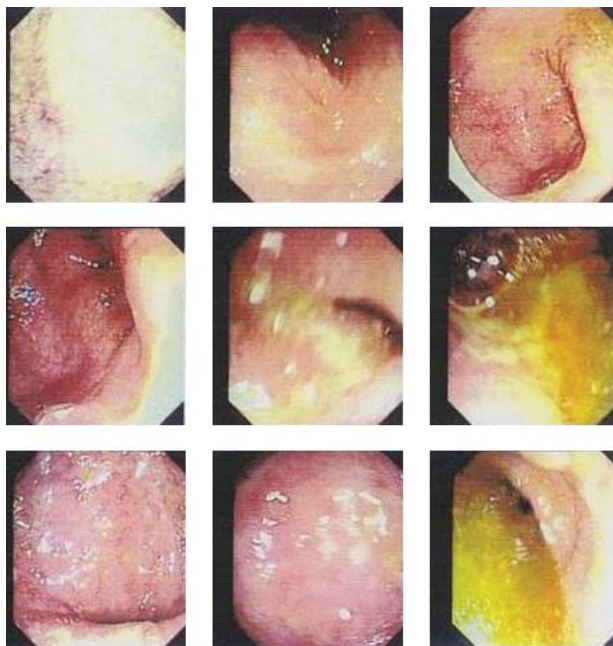


Figure 1: Endoscopic image of ulcerative colitis affecting the entire colon. The image shows inflamed, edematous, fragile colonic mucosa with superficial ulceration and loss of normal mucosal architecture.

phosphatase level, magnetic resonance collangiopancreatography (MRCP) was performed which revealed normal results.

The Naranjo Adverse Drug Reaction (ADR) Probability Scale (4) was used to evaluate the likelihood of a causal connection between isotretinoin treatment and aggravation of the symptoms in one patient with IBD. As shown in Table 1, our patient's score was calculated as 6 which showed a "probable" relationship. Isotretinoin treatment was discontinued after 40 days and the patient was prescribed 5-aminosalicylic acid and a course of steroids. After a few months she went into remission both clinically and by laboratory data based on Truelove and Witts Classification of the Severity of Ulcerative Colitis (4). Her ESR decreased and stool frequency per day was less than before. She has been subsequently seen in our clinic as an outpatient and is currently in clinical remission.

DISCUSSION

The association of isotretinoin and intestinal inflammation has received little attention in the medical literature, despite potential practical implications for physicians and patients alike. We presented the case of an Iranian patient with a history of isotretinoin consumption whose underlying ulcerative pancolitis worsened clinically whilst taking isotretinoin; cessation of the drug was associated with resolution of symptoms. Her score due to the Naranjo ADR Probability Scale was estimated as "probable".

The Naranjo ADR Probability Scale assigns a score from -2 to +2 for 10 questions that relate to causality. For questions with possible ambiguity, there are rules that have been developed to prevent subjectivity (Table 1). The total score from the sum of the 10 questions then classifies each case as "highly probable" (>8 points), "probable" (5-8 points), "possible" (1-4 points) or "doubtful" (0 points) regarding attribution to drug treatment (5).

Reddy et al. have evaluated 85 cases of IBD with histories of isotretinoin therapy over a 5 year period for the possibility of an association which was reported to the FDA (6). After the application of a causality index for each of these cases, it was noted that the majority (68%) were within the range for isotretinoin to be a "probable" cause of the patients' IBD, which was in concordance with our reported patient. However, four other cases (5%) in their study scored in the "highly probable" range with convincing data to support an even stronger association between isotretinoin use and onset of IBD. The researchers declared that

Table 1: Naranjo Adverse Drug Reaction Probability Scale and the score achieved by our patient

No.	Question	Answer			Patient's score
		Yes (max score)	No (min score)	Do not know	
1	Are there previous conclusive reports on this reaction?	+1	0	0	+1
2	Did the adverse event appear after the suspected drug was administered?	+2	-1	0	+1
3	Did the adverse reaction improve when the drug was discontinued or a specific antagonist was administered?	+1	0	0	+1
4	Did the adverse reactions appear when the drug was readministered?	+2	-1	0	0
5	Are there alternative causes (other than the drug) that could on their own have caused the reaction?	-1	+2	0	+2
6	Did the reaction reappear when a placebo was given?	-1	+1	0	0
7	Was the drug detected in the blood (or other fluids) in concentrations known to be toxic?	+1	0	0	0
8	Was the reaction more severe when the dose was increased or less severe when the dose was decreased?	+1	0	0	0
9	Did the patient have a similar reaction to the same or similar drugs in <i>any</i> previous exposure?	+1	0	0	0
10	Was the adverse event confirmed by any objective evidence?	+1	0	0	+1
Total Score			13		6

the Naranjo scale performed very well with regard to interpreter variability, with 98% concordance.

In addition to this case series report, other case studies have been published that favor this probable association. More recently, in 2009 a 32 year old man presented with a 3 week history of bloody diarrhea accompanied by abdominal pain (7). After ruling out other possible causes, treatment with isotretinoin was the only main probable risk factor for the onset of IBD in their case. The patient had started twice daily isotretinoin treatment one and a half years before the onset of his IBD. Similar to our patient, the disease course was changed to remission after the cessation of isotretinoin and administration of other appropriate drugs (7).

Although available data is so rare, it is probable that isotretinoin can cause intestinal inflammation in some patients, which is best demonstrated by the small

number in whom positive re-challenge experiences have been reported. Until 2010, the evidence was insufficient to confirm or refute a causal association between isotretinoin and IBD. In 2009, Bernstein et al. published a case-control study that has evaluated the association between isotretinoin and IBD using administrative claims data from Manitoba, Canada on 2008 cases of IBD and 19,814 matched controls. No association was found between isotretinoin usage either with ulcerative colitis (OR: 1.16; 95% CI: 0.56-2.20) or Crohn's disease (OR: 1.15; 95% CI: 0.61-2.02) (8). In contrast, a greater case-control study with a sample size of 8189 IBD patients and 21,832 controls was performed by Crockett et al. in 2010 (9). They showed that ulcerative colitis was strongly associated with previous isotretinoin exposure with a considerable OR of 4.36 (95% CI: 1.97-9.66). Nevertheless, no apparent association was shown between

isotretinoin and Crohn's disease (9). Similar to our patient, this was previously confirmed by other cases who mostly suffered from ulcerative colitis. Interestingly, Crockett et al. have also demonstrated a causal relationship between the dosage of isotretinoin and risk of IBD; they concluded that increased doses of isotretinoin were associated with elevated risk of ulcerative colitis (OR per 20 mg increase in dose: 1.50; 95% CI: 1.08-2.09). Compared with non-users, the risk of IBD was highest in those exposed to isotretinoin for more than 2 months (OR: 5.63; 95% CI: 2.10-15.03) (9). This study presented the strongest evidence published to date.

The pathogenesis of IBD involves a combination of proper genetic predisposition, immune dysregulation and some yet unidentified environmental exposures. Although the mechanism by which isotretinoin may cause IBD is still unknown, potential hypotheses exist. In view of the immunological effects, it is possible that isotretinoin acts as a trigger in an already susceptible patient. As previously well understood, retinoids (including isotretinoin) have diverse biologic activities that include natural killer T-cell stimulation, disturbed epithelial tissue growth, disruption of glycoprotein synthesis, apoptosis, or the effects of expressing growth factors, prostaglandins, or tumor necrosis factor (10,11). Therefore, it is proposed that isotretinoin may cause intestinal tissue injury. Additionally, this association could be based on the role of retinoic acid in lymphocyte migration and immuno-

modulation in the gut. It is hypothesized that retinoids may play a role in trafficking activated B cells to the gut mucosa (12).

Despite these possibilities and evidences, it is also suggested that the most probable cause of the development of IBD is the intake of isotretinoin. However, it is important to not overlook the possibility of coincidence in an undiagnosed patient with a subclinical course of IBD who consumes retinoids, as with our reported patient. It is theoretically possible that isotretinoin is associated with self-limited colitis that has been miscoded as ulcerative colitis.

With regards to all possible explanations for this relationship, our case of probable isotretinoin-aggravated IBD suggests that patients with suspected IBD should be asked about current or past use of isotretinoin in order to improve documentation of this serious adverse event. Although the absolute risk of developing ulcerative colitis after taking isotretinoin is likely quite small, clinicians prescribing isotretinoin as well as prospective patients should be aware of this possible association. In regards to the high proportion of young adults in Iran, more caution should be paid to the rather high use of isotretinoin in our country. Therefore, we suggest that when a patient under treatment with this isomer presents with symptoms suggestive of IBD, an endoscopic procedure should be performed in order to rule out inflammatory mucous changes. It is better not to recommend isotretinoin in patients with predisposing factors of IBD.

REFERENCES

1. Passier JL, Srivastava N, van Puijtenbroek EP. Isotretinoin-induced inflammatory bowel disease. *Neth J Med* 2006;64:52-4.
2. Product information Roaccutane. Genees- middeleninformatiebank, update February 2004 (www-cbg-meb.nl); Accessed 15 August 2010
3. Prokop LD. Isotretinoin: possible component cause of inflammatory bowel disease. *Am J Gastroenterol* 1999;94:2568.
4. Turner D, seow CH, Greenberg Gr, Griffiths AM, Silverberg MS, Steinhart AH. A Systematic Prospective Comparison of noninvasive disease activity indices in ulcerative Colitis. *Clin Gastroenterol Hepatol* 2009;7:1081-8.
5. Naranjo CA, Busto U, Sellers EM, Sandor P, Ruiz I, Roberts EA et al. A method for estimating the probability of adverse drug reactions. *Clin Pharmacol Ther* 1981;30:239-45.
6. Reddy D, Siegel CA, Sands BE, Kane S. Possible association between isotretinoin and inflammatory bowel disease. *Am J Gastroenterol* 2006;101:1569-73.
7. Papageorgiou NP, Altman A, Shoenfeld Y. Inflammatory Bowel Disease: Adverse Effect of Isotretinoin. *IMAJ* 2009;11:505-6.
8. Bernstein CN, Nugent Z, Longobardi T, Blanchard JF. Isotretinoin is not associated with inflammatory bowel disease: a population-based case-control study. *Am J Gastroenterol* 2009; 104: 2774-8
9. Crockett SD, Porter CQ, Martin CF, Sandler RS, Kappelman MD. Isotretinoin use and the risk of inflammatory bowel disease: a case-control study. *Am J Gastroenterol* 2010; 105:1986-93.
10. Leyden JJ. Retinoids and acne. *J Am Acad Dermatol* 1988;19:164-8.
11. Sarkar SA, Sharma RP. Expression of selected apoptosis related genes, MIF, IGIF and TNF alpha, during retinoic acid induced neural differentiation in murine embryonic stem cells. *Cell Struct Funct* 2002;27:99-107.
12. Mora JR. Homing imprinting and immunomodulation in the gut: role of dendritic cells and retinoids. *Inflamm Bowel Dis* 2008;14:275-89.