

# Multiple Pseudotumors of the Liver Associated with Adenocarcinoma of the Colon: A Case Report

**Tavakkoli H**<sup>1</sup>, **Ashrafi F**<sup>2</sup>, **Mahzouni P**<sup>3</sup>, **Ataabadi G**<sup>4</sup>, **Haghighi M**<sup>5</sup>

<sup>1</sup> Associate Professor, Department of Gastroenterology, Isfahan University of Medical Sciences , Isfahan, Iran

<sup>2</sup> Assistant Professor, Department of Hematology and Oncology, Isfahan University of Medical Sciences , Isfahan, Iran

<sup>3</sup> Associate Professor, Department of Clinical Pathology, Isfahan University of Medical Sciences , Isfahan, Iran

<sup>4</sup> Researcher, Isfahan University of Medical Sciences , Isfahan, Iran

<sup>5</sup> Associate Professor, Department of Radiology, Isfahan University of Medical Sciences , Isfahan, Iran

## ABSTRACT

Hepatic inflammatory pseudotumor (IPT) is a rare non-neoplastic process of unknown etiology, generally following a benign inflammatory condition. It is often mistaken as an either primary or metastatic malignancy in imaging studies. We report a 48 year-old female with numerous target lesions (2-4 cm) seen on high resolution ultrasound, spiral CT scan, and MRI in all liver lobes compatible with metastasis. Guided biopsies of the lesions were performed twice, but the pathologies showed no evidence of malignancy. Colonoscopy revealed adenocarcinoma of the colon. This case highlights liver pseudotumor in the differential diagnosis of hepatic tumoral lesions.

**Keywords:** Liver tumoral lesions; Pseudotumor; Colon adenocarcinoma

*Govareh/ Vol. 16, No.1, Spring 2011; 72-76*

## INTRODUCTION

Inflammatory pseudotumors (IPTs) are rare, benign tumors. They have been reported in the lungs(1), which is the most common site of occurrence , lymph nodes(2), skin(3), central nervous system(4), bladder(5), breast(6), salivary glands(7), pancreas(8), spleen(9), and liver(10). IPT of the liver is a rare, benign tumor-like lesion initially reported by Pack and Baker in 1953(11). Based on imaging findings,

IPT is sometimes misdiagnosed as a malignant tumor, e.g. hepatocellular carcinoma, cholangiocarcinoma or metastatic liver tumor(12-14). Due to their malignant appearance on imaging studies, an exploratory laparotomy or a hepatectomy is often performed(12-14). The needle liver biopsy is most useful for diagnosing IPT, as well as other hepatic mass lesions. Some cases of IPT of the liver have been associated with malignant tumors(15-19). The association of IPT with systemic inflammatory disorders has also been established and several cases with Crohn's disease(20), chronic hepatitis C(21), acute alcoholic hepatitis(22), and ascaris lumbricoides ova(23) have been reported. According to previous case reports, there are three types of cancers associated with hepatic IPT: gastrointestinal tract(18,19,24) biliary tract(15), and those which need systemic chemotherapy(16). We describe herein a case of hepatic pseudotumor accompanied by colon cancer, mimicking multiple liver metastases as diagnosed by percutaneous liver biopsy.

### Corresponding author:

Department of Gastroenterology, Alzahra Hospital,  
Soffeh Ave., Isfahan, Iran

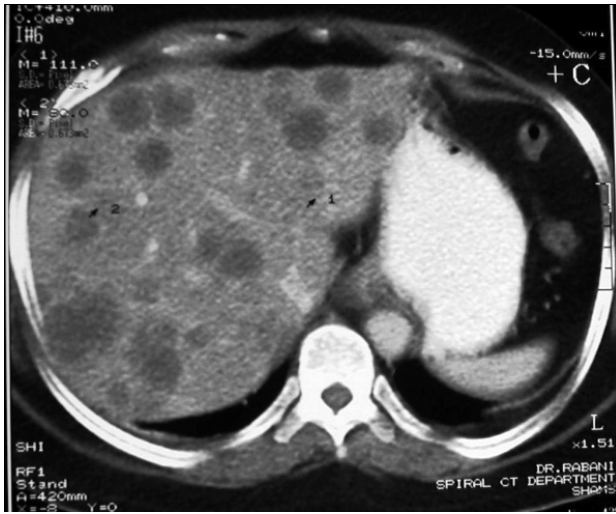
Telefax: + 98 3116684510

E-mail: [h\\_tavakoli@med.mui.ac.ir](mailto:h_tavakoli@med.mui.ac.ir)

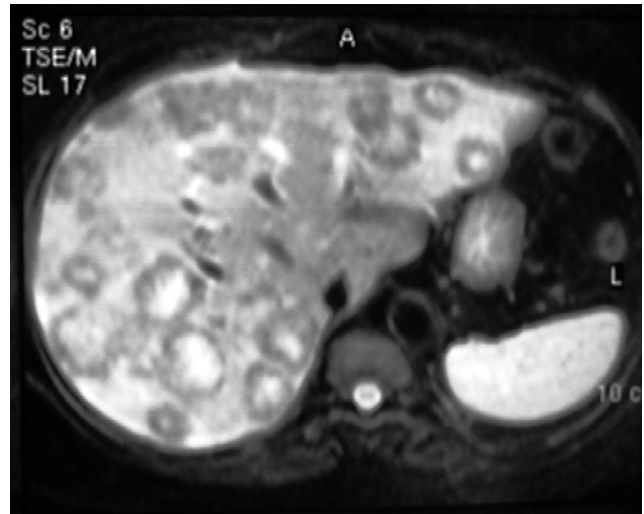Received : 10 Apr. 2011

Edited : 15 May 2011

Accepted : 17 May 2011



**Figure 1: Abdominal spiral CT scan:  
Multiple hypodense hepatic Lesions**



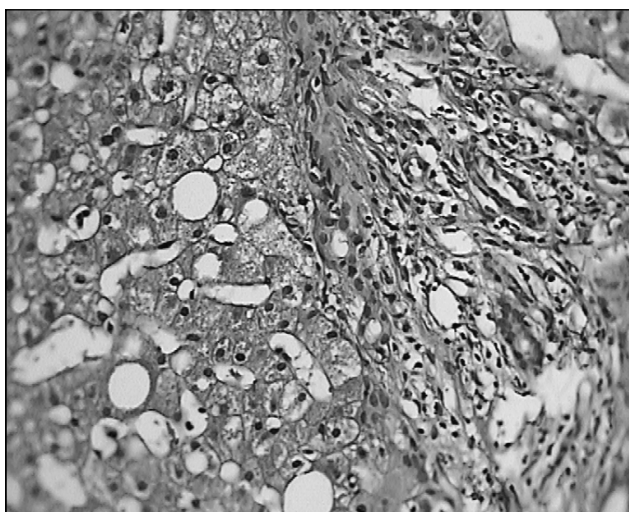
**Figure 2: Abdominal MRI:  
target Lesions of Liver on T2 Weight image**

### CASE REPORT

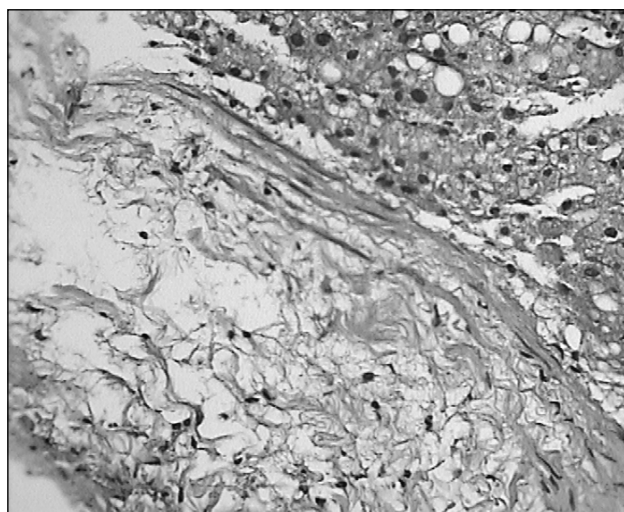
A 48 year-old woman referred to the outpatient gastroenterology clinic with sudden onset of severe upper right quadrant abdominal pain. On physical examination, the patient was not febrile, pale, or icteric. She appeared to be a healthy, well nourished middle aged woman. Abdominal examination revealed right upper quadrant tenderness and hepatomegaly. The liver surface was coarse, nodular and firm but the spleen was not palpable. Ultrasonography of the liver revealed numerous target lesions (2-4 cm in diameter). Laboratory tests revealed an erythrocyte sedimentation rate (ESR) of 80 mm/h and carcinoembryonic antigen (CEA) of 197 ng/ml (normal < 2.5 ng/ml), but other laboratory results that included hemoglobin, leukocytes, alanine aminotransferase (ALT), aspartate transaminase (AST), alkaline phosphatase, prothrombin time (PT), albumin, lactate dehydrogenase (LDH), and alpha-fetoprotein were all normal. Spiral CT scan revealed multiple hypodense masses in the right and left liver lobes on pre-contrast phase and rim enhancement on post-contrast arterial phase (Figure 1). MRI study of the abdomen displayed multiple hypointense masses on T1 weighted images and target lesions on T2 weighted images (solid lesions or abscesses) of the right and left liver lobes, but intrahepatic bile ducts were normal. No para-aortic lymphadenopathy was seen. All other intra-abdominal organs including spleen, kidneys, and pancreas

were normal (Figure 2). Ultrasound guided biopsy of the liver lesions was performed. Needle biopsy was composed of fragments of liver tissue. Infiltration of chronic inflammatory cells that included lymphocytes and a few plasma cells were evident in the portal areas. Both small and large droplets of fat were seen in a few hepatocytes (Figure 3). In the margin of one fragment, fibrosis, spindle cells and mixoid changes were observed (Figure 4). There was no evidence of malignancy.

Repeat CT guided biopsy confirmed the first pathologic findings and a diagnosis of hepatic pseudotumor was established. In further workups, upper GI endoscopy and colonoscopy were performed. Upper GI endoscopy was normal, but in the colonoscopy a tumoral lesion in the cecum was seen. Multiple biopsies were obtained and pathologic examination confirmed adenocarcinoma of the colon. In accordance to two pathologic reports of liver lesions and colonic adenocarcinoma, the diagnosis of hepatic pseudotumor and colon cancer was propounded and we recommended a hemicolectomy to the patient. She refused surgery, therefore she underwent a chemotherapy regimen of FOLFOX6 which was administered for six courses. Imaging studies of the liver repeated after three courses of chemotherapy showed a marked decrease in size and number of liver lesions on spiral CT scan. After completion of chemotherapy, the option of surgery was discussed again with the patient and a right hemi-



**Figure 3: Liver Pathology:**  
Lymphocytes and Plasma cell in the portal areas



**Figure 4: Liver Pathology:**  
fibrosis, spindle cells and mixoid changes in the margin

colectomy was performed.

## DISCUSSION

IPTs are more often seen in the Asian population and are three times more common in men than in women. The age range is from 9 months to 83 years with an average age at presentation of about 40 years. Although asymptomatic cases have been reported, they typically present with vague constitutional symptoms such as fever, nausea and vomiting, malaise, anorexia, weight loss, and abdominal pain. These nonspecific symptoms make preoperative diagnosis difficult(10,25,26).

Hepatomegaly with tenderness is often recognized in patients with IPT of the liver. Leukocytosis, increased ESR, and elevated serum C-reactive protein levels, suggestive of the presence of inflammation, are also common in laboratory findings (12) Often tumor markers, including alpha-fetoprotein and carcinoembryonic antigen, are normal while elevations in CA 19-9 have been reported(27,28). In imaging studies, IPTs usually present as solitary masses(29).

In our case, the prominent presenting features were right upper quadrant abdominal pain and tender hepatomegaly without fever or weight loss. All laboratory tests were normal except high ESR (suggestive of inflammation) and elevated CEA that has not been reported in previous cases of IPT. Normal alkaline phosphatase and lactate dehydrogenase in the pres-

ence of multiple hepatic masses were compatible with a diagnosis of IPT and against malignancy in our patient.

Histopathologically, IPT is a combination of plasma cells, macrophages, and fibroblasts with variable collagen deposition(17). The cellular composition of IPT is varied among cases. Even in the same lesion, the cellular composition may change over time. Since various histological features can be identified in a single lesion, histological criteria have not been proven helpful in the clinical management of these lesions other than to exclude malignancy(30). Although pathological findings in the present case could not strictly be diagnosed as classic IPT of the liver, this mixed histological feature may be a new variation of hepatic pseudotumor with mild fibrosis, inflammation, and steatosis.

The etiology and pathogenesis of IPT remain unclear. Many theories exist, however, including intraparenchymal hemorrhage and necrosis, infection, occlusive phlebitis of the intrahepatic veins, immune reaction, or secondary reaction to an intrahepatic rupture of a biliary radical(31). Perhaps the most popular theory suggests an infectious source as a cause. Some have hypothesized that microorganisms from certain conditions, such as appendicitis, seed the hepatic parenchyma through the bloodstream of the portal vein, creating an inflammatory reaction with obliterating phlebitis and granuloma formation(12).

IPT is sometimes misdiagnosed as a malignant tumor based on imaging findings. In several cases, IPT has been visualized as a hypoattenuating mass with a variable degree of hyperattenuation on enhanced CT scans, with the higher attenuation corresponding to the areas of intense fibrosis(32), and the areas of lower attenuation corresponding to the predominantly cellular areas. Despite their rarity, IPLs remain clinically important because of their differential diagnoses with both benign and malignant hepatic masses. Clinical, radiological, and histological data can help distinguish among IPLs and other liver diseases. Specifically, confirmation of the diagnosis can sometimes be made with core biopsy(33). Fine needle aspiration should be avoided, as the procedure leads to a high incidence of misdiagnosis(33). Despite over 75% of cases undergoing surgical resec-

tion, the optimum treatment method for hepatic IPT has not been established. There is no definite medical therapy. Spontaneous regression of the inflammatory lesions have been reported in several patients who have been observed without hepatic resection(34). In our patient, significant decrease of pseudotumors were seen after three months of chemotherapy with a FOLFOX6 regimen. The present case is unique because this is the first report of IPT with pathological findings of steatosis and elevated CEA in a patient with underlying colon cancer(24).

Inflammatory liver pseudotumor should be considered in the differential diagnosis of multiple hepatic masses and colon cancer as a rare underlying cause. Ultrasound or CT guided biopsy can be helpful for diagnosis.

## REFERENCES

1. Kobashi Y, Fukuda M, Nakata M, Irei T, Oka M. Inflammatory pseudotumor of the lung: clinicopathological analysis in seven adult patients. *Int J Clin Oncol* 2006;11:461-6.
2. Trevenzoli M, Cattelan AM, Lanzafame M, Sasset L, Concia E, Vento S. Inflammatory pseudotumor of lymph nodes. *Ann Med Interne (Paris)* 2003; 154:557-9.
3. Shabrawi-Caelen L, Kerl K, Cerroni L, Soyer HP, Kerl H. Cutaneous inflammatory pseudotumor--a spectrum of various diseases? *J Cutan Pathol* 2004;31:605-11.
4. Sitton JE, Harkin JC, Gerber MA. Intracranial inflammatory pseudotumor. *Clin Neuropathol* 1992;11:36-40.
5. Tunca F, Sanli O, Demirkol K, Gulluoglu M. Inflammatory pseudotumor of urachus mimicking invasive carcinoma of bladder. *Urology* 2006;67:623.
6. Khanafshar E, Phillipson J, Schammel DP, Minobe L, Cymerman J, Weidner N. Inflammatory myofibroblastic tumor of the breast. *Ann Diagn Pathol* 2005; 9:123-9.
7. Rahimi S, Mafera B, Vigili MG. Inflammatory pseudotumor of the parotid gland: report of a case with fine needle aspiration cytology. *Acta Cytol* 2004;48:574-6.
8. Palazzo JP, Chang CD. Inflammatory pseudotumour of the pancreas. *Histopathology* 1993;23:475-7.
9. Ma PC, Hsieh SC, Chien JC, Lao WT, Chan WP. Inflammatory pseudotumor of the spleen: CT and MRI findings. *Int Surg* 2007;92:119-22.
10. Locke JE, Choti MA, Torbenson MS, Horton KM, Molmenti EP. Inflammatory pseudotumor of the liver. *J Hepatobiliary Pancreat Surg* 2005;12:314-6.
11. Pack GT, Baker HW. Total right hepatic lobectomy; report of a case. *Ann Surg* 1953;138:253-8.
12. Horiuchi R, Uchida T, Kojima T, Shikata T. Inflammatory pseudotumor of the liver. Clinicopathologic study and review of the literature. *Cancer* 1990;65:1583-90.
13. Li GH, Li JQ, Lin YZ. Inflammatory pseudotumor of the liver. *J Surg Oncol* 1989;42:244-8.
14. Shek TW, Ng IO, Chan KW. Inflammatory pseudotumor of the liver. Report of four cases and review of the literature. *Am J Surg Pathol* 1993;17:231-8.
15. Akiyama T, Saito H, Kiriyama M, Tomita F, Kosaka T, Kita I et al. A case of gallbladder cancer associated with a common bile duct neuroma, and a cystic lesion of the liver with histologic findings similar to those of an inflammatory pseudotumor. *J Gastroenterol* 1995;30:408-12.
16. Isobe H, Nishi Y, Fukutomi T, Iwamoto H, Nakamuta M, Sakai H et al. Inflammatory pseudotumor of the liver associated with acute myelomonocytic leukemia. *Am J Gastroenterol* 1991;86:238-40.
17. Nishimura R, Teramoto N, Tanada M, Kurita A, Mogami H. Inflammatory pseudotumor of the liver associated with malignant disease: report of two cases and a review of the literature. *Virchows Arch* 2005;447:660-4.
18. Nishimura R, Mogami H, Teramoto N, Tanada M, Kurita A. Inflammatory pseudotumor of the liver in a patient with early gastric cancer: CT-histopathological correlation. *Jpn J Clin Oncol* 2005;35:218-20.
19. Saito K, Kotake F, Ito N, Tabuchi T, Goto Y, Katano M et al. Inflammatory pseudotumor of the liver in a patient with rectal cancer: a case report. *Eur Radiol* 2002;12:2484-7.
20. Amankonah TD, Strom CB, Vierling JM, Petrovic LM. Inflammatory pseudotumor of the liver as the first manifestation of Crohn's disease. *Am J Gastroenterol* 2001;96:2520-2.
21. Kim SR, Hayashi Y, Kudo M, Matsuoka T, Imoto S, Sasaki K et al. Inflammatory pseudotumor of the liver in a patient with chronic hepatitis C: difficulty in differentiating it from hepatocellular carcinoma. *Pathol Int* 1999;49:726-30.
22. Colli A, Massironi S, Faccioli P, Conte D. "Pseudotumor-

- al" hepatic areas in acute alcoholic hepatitis: a computed tomography and histological study. *Am J Gastroenterol* 2005;100:831-6.
23. Fogaca HS, Oliveira CS, Barbosa HT, Lanfredi RM, Chagas V. Liver pseudotumor: a rare manifestation of hepatic granulomata caused by *Ascaris lumbricoides* ova. *Am J Gastroenterol* 2000;95:2099-101.
  24. Ishida H, Tatsuta M, Furukawa H, Ohta H, Hashimoto K, Hayashi N, et al. Multiple inflammatory pseudotumors mimicking liver metastasis from colon cancer: report of a case. *Surg Today* 2000;30:530-3.
  25. Akatsu T, Wakabayashi G, Tanimoto A, Kameyama K, Kitajima M. Inflammatory pseudotumor of the liver masquerading as hepatocellular carcinoma after a hepatitis B virus infection: Report of a case. *Surg Today* 2006;36:1028-31.
  26. Maze GL, Lee M, Schenker S. Inflammatory pseudotumor of the liver and pregnancy. *Am J Gastroenterol* 1999;94:529-30.
  27. Ogawa T, Yokoi H, Kawarada Y. A case of inflammatory pseudotumor of the liver causing elevated serum CA19-9 levels. *Am J Gastroenterol* 1998;93:2551-5.
  28. Tsou UK, Lin CJ, Liu NJ, Lin CC, Lin CH, Lin SM. Inflammatory pseudotumor of the liver: Report of eight cases, including three unusual cases, and a literature review. *J Gastroenterol Hepatol* 2007;22:2143-7.
  29. Mortele KJ, Wiesner W, de Hemptinne B, Elewaut A, Praet M, Ros PR. Multifocal inflammatory pseudotumor of the liver: dynamic gadolinium-enhanced, ferumoxides-enhanced, and mangafodipir trisodium-enhanced MR imaging findings. *Eur Radiol* 2002;12:304-8.
  30. Lee SL, DuBois JJ. Hepatic inflammatory pseudotumor: case report, review of the literature, and a proposal for morphologic classification. *Pediatr Surg Int* 2001; 17:555-9.
  31. Standiford SB, Sobel H, Dasmahapatra KS. Inflammatory pseudotumor of the liver. *J Surg Oncol* 1989;40:283-7.
  32. Yoshikawa J, Matsui O, Kadoya M, Gabata T, Arai K, Takashima T. Delayed enhancement of fibrotic areas in hepatic masses: CT-pathologic correlation. *J Comput Assist Tomogr* 1992;16:206-11.
  33. Koea JB, Broadhurst GW, Rodgers MS, McCall JL. Inflammatory pseudotumor of the liver: demographics, diagnosis, and the case for nonoperative management. *J Am Coll Surg* 2003;196:226-35.
  34. Inaba K, Suzuki S, Yokoi Y, Ota S, Nakamura T, Konno H et al. Hepatic inflammatory pseudotumor mimicking intrahepatic cholangiocarcinoma: report of a case. *Surg Today* 2003;33:714-7.