

## Mesenteric Fibromatosis (Desmoid Tumor) Presenting as Recurrent Abdominal Abscess: Report of a Rare Case

**Nasser Ebrahimi-Daryani<sup>1</sup>, Ali-Reza Momeni<sup>2</sup>, Mohammad-Reza Azizi Asl<sup>3</sup>,  
Shahram Movafaghi<sup>4</sup>**

<sup>1</sup> Professor, Imam Hospital, Tehran University of Medical Sciences

<sup>2</sup> Researcher, Fellow of Gastroenterology, Tehran University of Medical Sciences

<sup>3</sup> Researcher, Tehran University of Medical Sciences

<sup>4</sup> Researcher, Pathologist, Laleh Hospital

### ABSTRACT

Aggressive fibromatosis or desmoid tumors, histologically indicated by small bundles of spindle cells in a fibrous background, are uncommon benign tumors without metastasis. They are recurrent and aggressive and their recurrence and severity is exacerbated following surgical operation. Based on previous reports, these tumors rarely present as intra-abdominal abscesses. Herein, a 54-year-old woman is presented who was referred with abdominal pain, fever, high ESR, and leukocytosis. On further evaluation, an intra-abdominal abscess was detected adjacent to splenic flexure of colon. Two months following antibiotic therapy, she came back with the same clinical presentation. In CT-scan, an abdominal mass was detected. Based on a CT-guided biopsy, presence of mesenteric fibromatosis was reported. The patient underwent a surgical operation and the tumor was resected.

**Keywords:** Fibromatosis, Desmoid, Abscess, Abdomen

*Govaresh/ Vol. 13, No.2, Summer 2008; 128-132*

### INTRODUCTION

Aggressive fibromatosis or desmoid tumors are rare tumors that consist about 0.03% of all neoplasms.(1), These tumors are usually associated with significant morbidity and mortality.(2), They have been reported more commonly in women and among patients aged 15 to 60 years.(3), They occur more frequently in patients with familial adenomatous polyposis (FAP) particularly those with Gardner's syndrome. This co-

incidence might be the possible etiology for 11% of its related mortality rate.(4, 5)

These tumors are histologically benign, but they behave like malignant tumors. They might invade locally and recur after excision.(5), They are histologically presented by small bundles of spindle cells in a fibrous background. The tumor cells show low mitosis with no necrosis. Immunohisto-chemical (IHC) study is always essential for differentiating them from other mesangial tumors.(6), Surgery is the treatment of choice of this tumor. Negative microscopic margins should be considered during the operation.(2)

### Corresponding author:

No. 130, Second Floor, Next to Zafar St., Shahid Naseri St., Vali-e-Asr Ave, Tehran, Iran

Tel: +98 21 8879 9446 Fax: +98 21 8879 98 40

E-mail: nasere@yahoo.com

Received: 4 Aug 2009 Edited: 4 Jan 2009

Accepted: 4 Jan 2009

### CASE PRESENTATION

A 54-year-old woman presented with mild ab-

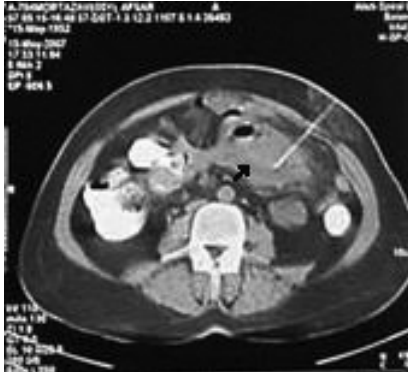dominal pain and relapsing fever, for 6 months . The abdominal pain has been mild, sustained and disseminated during the period. She also complained of a recurring fever with a temperature between 38.1 and 38.7 degree Celsius for the mentioned interval. She reported no changes in her bowel habit.

On admission, the patient was ill but not toxic. Blood pressure was 130/75 mmHg and a body temperature of 38 degree Celsius was recorded. She had mild tachycardia with a pulse rate of 110 pulses per minute. Conjunctiva was normal with no icterus or pallor. On abdominal examination, a moderately tender mass was palpated in the left upper quadrant. The mass was about 6 centimeters in diameter with poorly defined borders. It was fixed without any movement with respiration. Liver and spleen were normal. The abdomen was soft with normal bowel sounds. The rest of the physical examination including cardiac and pulmonary exams were normal. Laboratory tests revealed leukocytosis (white blood cell count=14200/ml<sup>3</sup>, neutrophils=78%, lymphocytes=22%), high erythrocyte sedimentation rate

(ESR=67 mm/h) and positive C-reactive protein (CRP=3+). Except for a raised serum alkaline phosphatase (335 IU/L, female normal range= 64-306 IU/L), other liver function tests were within normal limits. Laboratory tests are summarized in table 1. Abdominal ultrasound revealed a 67x72 millimeters cystic mass with two thick internal septal, thick wall, and intramural echogenic areas (gas or calcification) located in the left upper quadrant. Computed tomography (CT) scan also detected an abscess measuring 70x79 millimeters adjacent to the splenic flexure of colon with extension to the mesenteric root (Figure 1). Based on the culture of the contents of the abscess using a CT-guided aspiration (E-Coli was grown), intravenous ceftriaxone (1 gr/ bid) was administered for a period of 14 days followed by a 14-day course of oral cefixime (400 mg/day, single dose). Following the antibiotic therapy, the clinical manifestations subsided completely. Two months later, the patients came back with the same clinical picture including abdominal pain and fever (temperature equal to 39.6 degree Celsius). this time, a second CT scan was performed

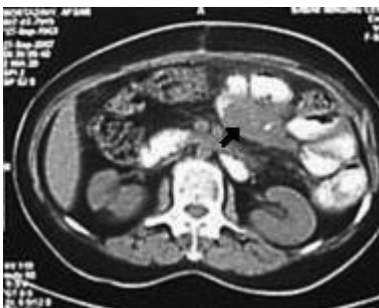**Table 1: Laboratory tests of the patients**

Laboratory Tests		Values	Units	Normal Ranges
Complete blood Count	WBC	14200	/ml <sup>3</sup>	4500-11000
	RBC	4.64	x10 <sup>6</sup> /ml <sup>3</sup>	4-5.2
	Hemoglobin	12.4	g/dl	12-16
	Hematocrit	38.8	%	36-46
	MCV	83.6	fL	78-102
	MCH	26.7	Pg/cell	26-34
	MCHC	32	g/dl	31-37
	RDW	13.3	%	11.5-14.5
	Platelets	564000	/mm <sup>3</sup>	150000-300000
ESR 1st Hour	67	mm/hr	<25 for age> 50y	
CRP	3+			
Creatinine	1.1	mg/dl	0.5-1.5	
Urea	41	mg/dl	17-43	
Uric Acid	7.5	mg/dl	1.5-6	
Bilirubin	Total	0.6	mg/dl	0.3-1
	Direct	0.2	mg/dl	0.1-0.3
SGOT (AST)	6	IU/L	<35	
SGPT (ALT)	7	IU/L	<35	
Alkaline Phosphatase	335	IU/L	64-306	

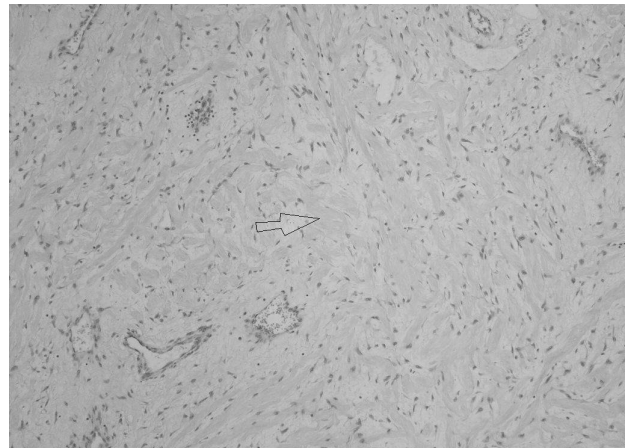


**Figure 1. CT-scan image: an abscess (arrow) measuring 70x79 millimeters predominantly adjacent to splenic colon flexure with extension in the mesenteric root**

that showed a 30x43 millimeters solid mass with ill-defined borders at the level of superior mesenteric vessels on the left side of mesentery (Figure 2). A CT-guided specimen was also sent for histology and immunoreactivity. Histology reported lipid connective tissue in addition to proliferation of completely differentiated fibroblasts (myofibroblasts) consisting of large spindle cells with small dense nuclei, scanty cytoplasm and ill-defined borders. Stroma was collagenised in some parts and mixoid in other regions with various degrees of vascularization. Mitotic index was less than 5 per HPFL (high power field). atypia was not detected. On Immunohistochemical staining the neoplastic cells were focally positive for desmin and CD-99. Smooth muscle actin was patchy positive. CD34 was positive in less than 10% of spindle cells. Vimentin, S100, CD-117(C-KIT), and EMA were negative.(Figure 3)



**Figure 2. CT-scan Image: a 30x43 millimeters solid mass (arrow) with ill-defined borders at the level of superior mesenteric vessels on left side of mesentery**



**Figure 3. Mesenteric Fibromatosis: proliferation of differentiated fibroblasts (myofibroblasts) consist of large spindle cells with small dense nucleus, low cytoplasm and ill-defined borders (arrow)**

With a diagnosis of mesenteric fibromatosis, the patient underwent laparotomy and the mass was resected. Due to extensive adhesions between the mass and adjacent tissues, the third and fourth parts of the duodenum and the first 40 centimeters of jejunum were also resected.

## DISCUSSION

Aggressive fibromatosis or desmoid tumors are uncommon mesenchymal tumors. They grow slowly and originate from musculo-aponeurotic elements. These tumors are locally invasive and may even lead to death by destruction of adjacent vital organ, although no metastasis has been reported for these tumors. (7)

Desmoid tumors are categorized based on their location into intra- and extra- abdominal tumors. Extra-abdominal tumors which are sporadic can be treated effectively by local therapy. Systemic therapy might be used in recurrent cases. Intra-abdominal tumors, especially if they occur in (FAP), are surgically unresectable because they are accompanied with diffuse mesenteric infiltration and surgical operation leads to an even more invasive recurrence. (8, 9), Therefore, desmoid tumors accompanied with FAP (Gardner's syndrome) have reported to be more invasive with

higher local relapses rates. (10), Desmoid tumors usually present as a slow growing mass with or without mild pain. Intra-abdominal types may present with bowel obstruction, mucosal ischemia, and functional impairment of ileoanal anastomosis following colectomy in FAP patients. Extra-abdominal tumors can be formed in any area, but they are more likely to be found in the limbs, especially over pelvic, or shoulder girdles.(11, 12), Etiology of these tumors is unknown. Trisomy of chromosomes 8 or 20, single or together, are seen in about one third of patients with sporadic type.(13), These genetic disorders are accompanied with more local relapses. (14, 15) Based on previous studies, the following factors have been identified as poor prognostic ones: age between 18 and 30 years, locally recurrent disease, incomplete tumor resection, and lack of performing radiotherapy following surgery. (7)

These tumors can not be differentiated from other soft tissue tumors using radiologic findings. CT scan and MRI show its resectability and adhesion to neighboring tissues. Histologic examination of the tumor is the only means for definite diagnosis. Tumors located in the abdominal wall and extra-abdominal tumors, compared with intra-abdominal types, are more likely to be unavailable to surgical resection. Surgery in intra-abdominal tumors is difficult or sometimes impossible. Therefore, medical treatment might be the first choice in these cases, especially in tumors involving blood vessels or mesentery. (16), Local relapse rates of 23% to 39% have been reported even after complete resection with enough clear margins.(9), In patients who are not good candidates for surgery or do not consent for operation, radiotherapy is a proper choice For regression of the tumor following radiotherapy, sometimes a long period of time (may be up to a few years) is needed. Radiotherapy has been reported to have good long term results in 70 to 80% of cases with involved margins at operation. Size of tumor is not a selective measure for radiotherapy.(17) Ra-

diotherapy (with or without surgery), compared to surgery (alone), leads to better five years survival. radiotherapy (alone), has better results in relation to the other two methods. (2), Neo-adjuvant radiotherapy (performing radiotherapy before surgery) is a new approach with promising results.(18)

## CONCLUSION

Intra-abdominal fibromatosis or desmoid tumors are usually present a slow growing mass with mild pain. Abdominal abscesses with local recurrence should also raise the possibility of these tumors.

## References

1. Reitamo JJ, Hayry P, Nykyri E, Saxen E. The desmoid tumor. I. Incidence, sex-, age- and anatomical distribution in the Finnish population. *Am J Clin Pathol* 1982 ;77:665-73.
2. Nuyttens JJ, Rust PF, Thomas CR, Jr., Turrisi AT, 3rd. Surgery versus radiation therapy for patients with aggressive fibromatosis or desmoid tumors: A comparative review of 22 articles. *Cancer* 2000 ;88:1517-23.
3. Hansmann A, Adolph C, Vogel T, Unger A, Moeslein G. High-dose tamoxifen and sulindac as first-line treatment for desmoid tumors. *Cancer* 2004;100:612-20.
4. Arvanitis ML, Jagelman DG, Fazio VW, Lavery IC, McGannon E. Mortality in patients with familial adenomatous polyposis. *Dis Colon Rectum* 1990;33:639-42.
5. Clark SK, Neale KF, Landgrebe JC, Phillips RK. Desmoid tumours complicating familial adenomatous polyposis. *Br J Surg* 1999 ;86:1185-9.
6. Jemal A, Siegel R, Ward E, Murray T, Xu J, Thun MJ. Cancer statistics, 2007. *CA Cancer J Clin* 2007 ;57:43-66.
7. Posner MC, Shiu MH, Newsome JL, Hajdu SI, Gaynor JJ, Brennan MF. The desmoid tumor. Not a benign disease. *Arch Surg* 1989 ;124:191-6.
8. Spear MA, Jennings LC, Mankin HJ, Spiro IJ, Springfield DS, Gebhardt MC, et al. Individualizing management of aggressive fibromatoses. *Int J Radiat Oncol Biol Phys* 1998 ;40:637-45.
9. Karakousis CP, Mayordomo J, Zografos GC, Driscoll DL. Desmoid tumors of the trunk and extremity. *Cancer* 1993 ;72:1637-41.
10. Kadmon M, Moslein G, Buhr HJ, Herfarth C. [Desmoid tumors in patients with familial adenomatous polyposis (FAP). Clinical and therapeutic observations from the Heidelberg polyposis register]. *Chirurg* 1995 ;66:997-1005.
11. Church JM. Mucosal ischemia caused by desmoid tumors in

- patients with familial adenomatous polyposis: report of four cases. *Dis Colon Rectum* 1998;41:661-3.
- 12.Sagar PM, Moslein G, Dozois RR. Management of desmoid tumors in patients after ileal pouch-anal anastomosis for familial adenomatous polyposis. *Dis Colon Rectum* 1998 ;41:1350-5.
  - 13.De Wever I, Dal Cin P, Fletcher CD, Mandahl N, Mertens F, Mitelman F, et al. Cytogenetic, clinical, and morphologic correlations in 78 cases of fibromatosis: a report from the CHAMP Study Group. *CHromosomes And Morphology. Mod Pathol* 2000 ;13:1080-5.
  - 14.Fletcher JA, Naeem R, Xiao S, Corson JM. Chromosome aberrations in desmoid tumors. Trisomy 8 may be a predictor of recurrence. *Cancer Genet Cytogenet* 1995 ;79:139-43.
  - 15.Kouho H, Aoki T, Hisaoka M, Hashimoto H. Clinicopathological and interphase cytogenetic analysis of desmoid tumours. *Histopathology* 1997 ;31:336-41.
  - 16.Middleton SB, Phillips RK. Surgery for large intra-abdominal desmoid tumors: report of four cases. *Dis Colon Rectum* 2000 ;43:1759-62.
  - 17.Acker JC, Bossen EH, Halperin EC. The management of desmoid tumors. *Int J Radiat Oncol Biol Phys*1993 ;26:851-8.
  - 18.O'Dea FJ, Wunder J, Bell RS, Griffin AM, Catton C, O'Sullivan B. Preoperative radiotherapy is effective in the treatment of fibromatosis. *Clin Orthop Relat Res* 2003; 415:19-24.