

# Endoscopic Ultrasonography in Patients with Chronic Liver Disease: A Case Control Study

Sotoudehmanesh R<sup>1</sup>, Ainechi S<sup>2</sup>, AliAsgari A<sup>3</sup>, Kolahdoozan S<sup>2</sup>

<sup>1</sup>Associate Professor, Digestive Disease Research Institute, Shariati Hospital, Tehran University of Medical Sciences, Tehran, Iran

<sup>2</sup>Disease Research Institute, Shariati Hospital, Tehran University of Medical Sciences, Tehran, Iran

<sup>3</sup>Department of Internal Medicine, Tehran University of Medical Sciences, Tehran, Iran.

## ABSTRACT

**Background :** The portal system and azygos vein are the main drainage systems during portal hypertension. This study aims to compare the diameter of these veins by endoscopic ultrasonography (EUS) in patients with and without chronic liver disease (CLD).

**Materials and Methods :** During one year, patients with CLD enrolled as the study group. Patients who underwent EUS for other reasons during the same period served as controls. In cases with CLD, we assessed the relationship between degrees of hepatic dysfunction (Child-Pugh class), history of variceal bleeding, presence of hyponatremia, thrombocytopenia, and endoscopic grading of varices with the sizes of the portal, splenic, and azygos veins on EUS.

**Results :** During the study period, there were 63 patients (20 females and 43 males) with CLD and 85 control subjects (42 females and 43 males) enrolled. The mean ages of cases was  $45.60 \pm 14$  years and controls was  $48.5 \pm 15$  years. The most common cause of CLD was post-necrotic cirrhosis due to hepatitis B virus. Patients with CLD had significantly higher mean portal, splenic, and azygos vein diameters than the control group ( $p < 0.001$ ). With azygos, portal, and splenic vein diameters of 10, 11 and 9 mm, sensitivity for the diagnosis of portal hypertension was 66%, 71%, and 66%, while specificity was 94%, 99% and 99%, respectively. Splenic and portal vein dilation, and thrombocytopenia significantly correlated with variceal bleeding ( $p < 0.05$ ).

**Conclusion :** EUS allows for the collection of valuable quantitative data from the portal system, the diagnosis of portal hypertension, and follow up of patients with CLD.

**Keywords :** Hypertension; portal; Endosonography; Liver cirrhosis; Diagnosis

Govareh/ Vol. 16, No.4, Winter 2012; 270-274

## INTRODUCTION :

Portal hypertension, a main consequence of cirrhosis, is responsible for its most common complications, including variceal bleeding. The development of

portal hypertension causes diversion of blood from the drainage bed of the portal vein to that of the azygos system via the intrinsic and extrinsic veins of the proximal stomach and the distal esophagus, causing dilation and tortuosity of these veins. Traditionally, the focus of attention in portal hypertension has been the development of intramural varices around the gastroesophageal junction. This has been partly due to the clinical significance of the variceal rupture, as well as the ability with conventional endoscopy to assess only such varices. Predicting the presence of portal hypertension, and consequently esophageal varices, through other methods is of importance because approximately half of the patients do not have esophageal varices on screening endoscopy. In a retrospective study that has been performed in 255

## Corresponding author:

Digestive Disease Research Institute, Shariati Hospital, Tehran University of Medical Sciences, Tehran, Iran

Tel : + 98 21 84902277

Fax : + 98 21 82415104

E-mail: r.sotoudehmanesh@ams.ac.ir

Received : 10 Oct. 2011

Edited : 15 Dec. 2011

Accepted : 17 Dec. 2011

patients with primary sclerosing cholangitis, platelet counts ( $<150,000/\text{dl}$ ), albumin levels, and advanced histologic disease were independent predictors of esophageal varices(1).

Although the use of endoscopic ultrasonography (EUS) in evaluation of portal hypertension in cirrhotic patients has been reported in many studies(2-6), trans-abdominal ultrasound is the standard method for the evaluation of the portal venous system and detection of ascites in these patients. However, EUS can demonstrate periesophageal and perigastric collaterals and azygos veins in addition to portal and splenic veins (7,8).

There are controversial results in the relation between the inner-diameter of portal, splenic, and azygos veins with Child-Pugh classification, variceal bleeding or ascites(9,10). This study aims to assess the value of EUS findings in patients with chronic liver disease (CLD) for the detection of portal hypertension and to compare venous diameters of patients with and without variceal bleeding.

## MATERIALS AND METHODS :

### Patients

The study group consisted of patients with CLD who had esophageal varices, splenomegaly, or ascites as indicators of portal hypertension. The diagnosis of CLD was based on liver biopsy or clinical (hepatic encephalopathy, spider angioma, ascites, and esophageal or gastric varices) and laboratory (prolonged prothrombin time, low serum albumin levels, and high serum-ascites albumin gradient) findings. Exclusion criteria were pregnancy, contraindication for endoscopy, age younger than 15 years, previous variceal sclerotherapy, previous history of surgery for portal hypertension, and any malignant conditions. Patients with newly diagnosed variceal bleeding were assessed by EUS after hemodynamic stability, either before or one day after the first session of variceal ablation. Control patients had no evidence for CLD, but were referred for evaluation of common bile duct stones and submucosal upper gastrointestinal lesions by EUS.

In addition to the demographic characteristics of the study and control groups, in the study group the etiology of CLD, history of previous variceal bleeding, presence of splenomegaly, history of hepatic encephalopathy, ascites, serum albumin, bilirubin, prothrombin time, and platelet counts were recorded. Thrombocytopenia was defined as a platelet count of less than  $100,000/\mu\text{l}$ .

The study was approved by the Institutional Review Board of the Digestive Disease Research Center of Tehran University of Medical Sciences and written informed consent was obtained from every patient.

### Endoscopy and EUS

All cases with CLD underwent standard upper esophagogastroduodenoscopy with a videoendoscopy system (GIF-160; Olympus, Japan). The presence of varices and their endoscopic gradings were evaluated. The endosonographer was blinded for upper gastrointestinal endoscopy findings. After esophagogastroduodenoscopy, patients underwent EUS (radial GF-UMQ 240 Echoendoscope Olympus) with 7.5 MHz frequency. Using EUS, the diameters of the portal, splenic, and azygos veins were measured. The azygos vein was imaged through the distal esophagus and the maximal diameter measured just before reaching the azygos arch. A water-filled balloon was used to better visualize the images.

### Data analysis

Endosonographic data were compared between control and case groups. Quantitative variables were expressed as mean  $\pm$  SD and compared using the student's t-test and analysis of variance. Qualitative variables were compared using the Pearson chi-square test or Fisher's exact test. P-values were calculated and  $p < 0.05$  was considered statistically significant.

## RESULTS :

During one year, 63 CLD patients (20 females and 43 males; mean age  $45.60 \pm 14$  years) and 85 control cases (42 females and 43 males; mean age  $48.5 \pm 15$  years) were enrolled. The most common cause of CLD was

**Table 1:** Azygos, portal and splenic vein diameters in study and control patients.

EUS finding (Mean-mm)	Cirrhotic group N=63	Control group N=85	p-value
Azygos vein	$11.69 \pm 2.27$	$7.98 \pm 1.56$	$<0.001$
Portal vein	$12.78 \pm 2.89$	$8.70 \pm 1.75$	$<0.001$
Splenic vein	$10.46 \pm 2.66$	$6.68 \pm 1.36$	$<0.001$

post-necrotic cirrhosis due to hepatitis B virus. Table 1 compares azygos, portal, and splenic vein diameters between case and control groups.

Based on ROC curve analysis (Figure 1) we calculated the best cut-off values with which to diagnose portal hypertension by using venous diameters (Table 2).

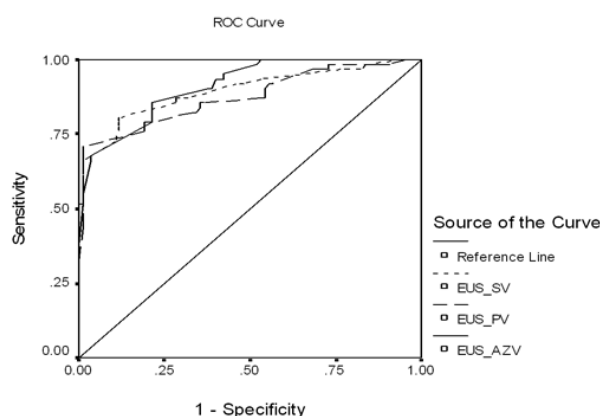


Fig. 1: ROC curve for azygos, portal, and splenic vein diameters in patients with and without chronic liver disease (CLD).

Table 2: Cut-off values for the diagnosis of portal hypertension.

Venous system	Cut-off (mm)	Sensitivity (%)	Specificity (%)
Azygos vein	10	66	94
Portal vein	11	71	99
Splenic vein	9	66	99

There was no significant relationship found between the presence of ascites, Child-Pugh class, hyponatremia, splenomegaly, and endoscopic grading of varices with azygos, splenic, and portal vein diameters in patients with CLD.

In patients with CLD, the splenic vein diameter (11.5 vs. 9.7 mm,  $p=0.006$ ), portal vein diameter (13.65 vs. 12.17 mm,  $p=0.04$ ) and platelet counts (80,500 vs. 123,000/ $\mu$ l,  $p=0.003$ ) significantly correlated with variceal bleeding.

There was no significant difference between mean albumin, impaired prothrombin time, and bilirubin in cases with or without variceal bleeding.

Table 3 compares portal, splenic, and azygos vein diameters in CLD patients without histories of esophageal bleeding (EVB<sup>-</sup>) and those with histories of esophageal bleeding (EVB<sup>+</sup>).

Table 3: EUS findings in CLD patients with and without variceal bleeding.

EUS finding (Mean-mm)	EVB <sup>-</sup> (n=37)	EVB <sup>+</sup> (n=25)	p-value
Azygos vein	11.52	11.94	>0.05
Portal vein	12.17	13.65	<0.05
Splenic vein	9.70	11.55	<0.05

### DISCUSSION :

This study showed that patients with CLD had significantly higher mean venous diameters than the control group. In addition, the cut-off values of the portal system and azygos vein for the diagnosis of portal hypertension was determined. Finally, thrombocytopenia and portal and splenic vein dilation significantly correlated with a history of variceal bleeding in patients with CLD.

Our significant findings were the differences between patients with or without portal hypertension in the diameters of the azygos, splenic, and portal veins. These findings agreed with other studies(11,12) and contrasted the study of Burtin et al.(13) who found that EUS had limited value in the diagnosis of portal hypertension.

Some studies(7,14) have shown that the azygos vein is dilated during portal hypertension, while other studies(13) have not. Although Faigel et al.(11) showed a relationship between azygos vein diameter and Child-Pugh's class of cirrhotic patients, our study agreed with Kassem et al.(15) who found no relationship.

Although EUS may not be the best method for diagnosis of portal hypertension, the presence of enlarged portal, splenic, and azygos veins should cause suspicion of cirrhosis and portal hypertension in a patient undergoing EUS.

We found the best cut-off value for the diagnosis of portal hypertension in patients with CLD. However by using transabdominal ultrasound, studies have shown that main portal vein diameters larger than 13 mm (specificity 95-100%, sensitivity 42%) and splenic vein diameters larger than 10 mm are indicative of portal hypertension(16,17). Shen et al.(18) have also shown cut-off values of 8 mm for splenic vein diameter (76.7% specificity, 60.0% sensitivity) and 12 mm for main portal vein (44.6% specificity, 78.6% sensitivity), using transabdominal ultrasound for the diagnosis of portal hypertension. The correlation between transabdominal and EUS

findings for measurement of portal system diameter need further study.

The assessment of bleeding risk in a patient with end-stage liver disease, complicated by portal hypertension and gastroesophageal varices, is a potentially important clinical application of EUS. The landmark study by the Northern Italian Endoscopy Club (NIEC) (19) identified variceal size, degree of liver failure, and endoscopic red signs as major independent predictors of an index episode of variceal bleeding. However, subsequent attempts (20,21) to validate these criteria have found the original NIEC prognostic index to have lower predictive values than originally anticipated. These studies indicate that variceal size and red signs play a more important role, while liver failure plays a less important role, in the prediction of future variceal hemorrhage. Standard endoscopy as a method of assessment has not been shown to be substantially superior to the NIEC criteria (21). Therefore, there is a need for better methods to assess the risk of variceal hemorrhage.

Recently some variables, such as portal vein diameter greater than 13 mm, platelet counts less than 80,000/ $\mu$ L, splenomegaly (or spleen volume index  $\geq 45$ ), have been introduced to predict the risk of variceal bleeding (1,19,22-24,25). A positive history of

variceal bleeding was significantly related to splenic vein diameter in our study.

The increased blood flow volume of the splenic vein seen in duplex Doppler ultrasonography and the engorgement of the splenic vein in conventional ultrasonography can be among the first predictive signs of esophageal variceal formation (26). The same findings in two prior studies indicate that the increase in splenic vein flow may thus play a role in the development of EVB (10,26). Although in these studies the splenic vein flow was the main data investigated, the enlargement of the splenic vein (as an independent sign of portal hypertension) also had significant correlation.

In our study, the presence of thrombocytopenia had a significant relationship with dilated splenic and the risk of EVB. This finding has also been explained by congestive splenomegaly and resulting hypersplenism. Studies (1, 27,28). have shown platelet count to be a risk factor for the presence of large varices. Thus, thrombocytopenia might be a risk factor for variceal bleeding.

In conclusion, EUS may be a useful method for the detection of cases that have greater risk for recurrence of varices and subsequent bleeding. Our findings should be confirmed by other studies.

## REFERENCES

1. Zein CO, Lindor KD, Angulo P. Prevalence and predictors of esophageal varices in patients with primary sclerosing cholangitis. *Hepatology* 2004;39:204-10.
2. Caletti GC, Bolondi L, Zani L, Brocchi E, Guizzardi G, Labo G. Detection of portal hypertension and esophageal varices by means of endoscopic ultrasonography. *Scand J Gastroenterol Suppl* 1986; 123:74-7.
3. Caletti G, Brocchi E, Zani L, Barbara L. The important role of EUS in the assessment of patients with portal hypertension. *Gastrointest Endosc* 1988;34:154-5.
4. Sukigara M, Komazaki T, Yamazaki T, Anzai H, Koyama I, Omoto R. Colour flow mapping of oesophagogastric varices and vessels in and around the liver with trans-oesophageal real-time two-dimensional Doppler ultrasound. *Clin Radiol* 1987;38:487-94.
5. El-Saadany M, Jalil S, Irisawa A, Shibukawa G, Ohira H, Bhutani MS. EUS for portal hypertension: a comprehensive and critical appraisal of clinical and experimental indications. *Endoscopy* 2008;40:690-6.
6. Ginès A, Fernández-Esparrach G. Endoscopic ultrasonography for the evaluation of portal hypertension. *Clin Liver Dis* 2010;14:221-9.
7. Kassem AM, Salama ZA, Rosch T. Endoscopic ultrasonography in portal hypertension. *Endoscopy* 1997;29:399-406.
8. Salama ZA, Kassem AM, Giovannini M, Hunter MS. Endoscopic ultrasonographic study of the azygos vein in patients with varices. *Endoscopy* 1997;29:748-50.
9. Liu Y, Li L, Yu Z, Liu Q, Li Z, Wang Y, et al. Correlative study between portal vein pressure and portal hemodynamics in patients with portal hypertension. *Zhonghua Gan Zang Bing Za Zhi* 2002; 10:135-7.
10. Kayacetin E, Efe D, Dogan C. Portal and splenic hemodynamics in cirrhotic patients: relationship between esophageal variceal bleeding and the severity of hepatic failure. *J Gastroenterol* 2004;39:661-7.
11. Faigel DO, Rosen HR, Sasaki A, Flora K, Benner K. EUS in cirrhotic patients with and without prior variceal hemorrhage in comparison with noncirrhotic control subjects. *Gastrointest Endosc* 2000; 52:455-62.
12. Irisawa A, Obara K, Sato Y, Saito A, Takiguchi F, Shishido H, et al. EUS analysis of collateral veins inside and outside the esophageal wall in portal hypertension. *Gastrointest Endosc* 1999;50:374-80.
13. Burtin P, Cales P, Oberti F, Joundy N, Person B, Carpentier S, et al. Endoscopic ultrasonographic signs of portal hypertension in cirrhosis. *Gastrointest Endosc* 1996;44:257-61.
14. Caletti G, Brocchi E, Baraldini M, Ferrari A, Gibilaro M, Barbara L. Assessment of portal hypertension by endoscopic

- ultrasonography. *Gastrointest Endosc* 1990;36:S21-S7.
15. Kassem AM, Salama ZA, Zakaria MS, Hassaballah M, Hunter MS. Endoscopic ultrasonographic study of the azygos vein before and after endoscopic obliteration of esophago-gastric varices by injection sclerotherapy. *Endoscopy* 2000;32:630-4.
  16. Bolondi L, Gandolfi L, Arienti V, Caletti GC, Corcioni E, Gasbarrini G, et al. Ultrasonography in the diagnosis of portal hypertension: diminished response of portal vessels to respiration. *Radiology* 1982; 142:167-72.
  17. Zwiebel WJ. Sonographic diagnosis of hepatic vascular disorders. *Semin Ultrasound CT MR* 1995;16:34-48.
  18. Shen L, Li JQ, Zeng MD, Fan ST, Lu LG, Bao H, et al. Evaluation of the value of ultrasonography in diagnosis of liver fibrosis in patients with chronic viral hepatitis. *Zhonghua Gan Zang Bing Za Zhi* 2005; 13:117-20.
  19. North Italian Endoscopic Club for the Study and Treatment of Esophageal Varices. Prediction of the first variceal hemorrhage in patients with cirrhosis of the liver and esophageal varices. A prospective multicenter study. *N Engl J Med* 1988;319:983-9.
  20. Colombo E, Casiraghi MA, Minoli G, Prada A, Terruzzi V, Bortoli A, et al. First bleeding episode from oesophageal varices in cirrhotic patients: a prospective study of endoscopic predictive factors. *Ital J Gastroenterol* 1995;27:345-8.
  21. Rigo GP, Merighi A, Chahin NJ, Mastronardi M, Codeluppi PL, Ferrari A, et al. A prospective study of the ability of three endoscopic classifications to predict hemorrhage from esophageal varices. *Gastrointest Endosc* 1992;38:425-9.
  22. Adrover R, Cocozzella D, Borzi S, Montenegro L, Defelitto M, Bosia D, et al. When is the best time to perform upper digestive endoscopy to detect the presence of esophageal varices in patients with cirrhosis?. *Gastroenterol Hepatol* 2004;27:353-6.
  23. Bocus P, Ceolin M, Battaglia G. Endoscopic ultrasonography (EUS) in portal hypertension. *Minerva Med* 2007;98:431-6.
  24. Chalasani N, Imperiale TF, Ismail A, Sood G, Carey M, Wilcox CM, et al. Predictors of large esophageal varices in patients with cirrhosis. *Am J Gastroenterol* 1999;94:3285-91.
  25. Jensen DM. Endoscopic screening for varices in cirrhosis: findings, implications, and outcomes. *Gastroenterology* 2002;122:1620-30.
  26. Yin XY, Lu MD, Huang JF, Xie XY, Liang LJ. Color Doppler velocity profile assessment of portal hemodynamics in cirrhotic patients with portal hypertension: correlation with esophageal variceal bleeding. *J Clin Ultrasound* 2001;29:7-13.
  27. Schepis F, Camma C, Niceforo D, Magnano A, Pallio S, Cinquegrani M, et al. Which patients with cirrhosis should undergo endoscopic screening for esophageal varices detection? *Hepatology* 2001; 33:333-8.
  28. Zaman A, Becker T, Lapidus J, Benner K. Risk factors for the presence of varices in cirrhotic patients without a history of variceal hemorrhage. *Arch Intern Med* 2001;161:2564-70.