

Report of a Case of Hepatic Epithelioid Hemangioendothelioma

Ebrahimi Daryani N¹, Zare Mehrjardi A², Samadi Ghooshchi A³, Keramati MR³, Nayer Habibi A³

¹ Professor, Department of Gastroenterology, Imam Khomeini Hospital, Tehran University of Medical Sciences

² Associate professor, Iran University of Medical Sciences

³ Research fellow, Imam Khomeini Hospital, Tehran University of Medical Sciences

ABSTRACT

Epithelioid hemangioendothelioma (EHE) is a rare neoplasm of vascular origin which arises preferentially in soft tissue and bone, and rarely in the liver. Its vascular nature is confirmed by positive staining for factor VIII-related antigen and other endothelial cell markers (CD31, CD34) in addition to the pathologic characteristics of well-developed basal lamina, pinocytotic vesicles, and, more specifically, Weibel-Palade bodies. Immunohistochemical identification of factor VIII-related antigen is helpful in differentiating metastatic carcinoma from primary epithelial liver tumors. To the best of our knowledge, no patient with EHE of liver has been reported yet from our region. Herein, we present a 56-year-old man who presented with one episode of severe epigastric pain and finally diagnosed as having EHE of liver. .

Keywords: Epithelioid hemangioendothelioma, Liver neoplasms, Liver transplantation

Govaresh/ Vol. 12, No. 2, Summer 2007; 134-138

Received: 9-8-2007

Edited: 9-9-2007

Accepted: 9-9-2007

INTRODUCTION

Epithelioid hemangioendothelioma (EHE) is a rare neoplasm of vascular origin which arises preferentially in soft tissue and bone, and rarely in the liver. The clinical and morphologic features of EHE are a spectrum with benign hemangioma in one side and malignant hemangioendotheliosarcoma on the other side.^(1, 2) Its vascular nature is supported by the detection of a positive staining for factor VIII-related antigen, specifically by the so-called "Weibel-Palade bodies." Immunohistochemical identification of factor VIII-related antigen is essential to distinguish hepatic EHE from metastatic carcinoma or primary liver tumors.⁽³⁾

Corresponding author:

Naser Ebrahimi Daryani, No. 130, Second Floor, Next to Zafar St., Shahid Naseri St., Vali-e-Asr Avenue, Tehran.

Tel: +98 21 8879-9446

Fax: +98 21 8879-9840

E-mail: nasere@yahoo.com

The hepatic form of EHE usually behaves as a low-grade tumor, which is derived from endothelial cells. The etiology of the disease still remains undetermined; however, previous use of oral contraceptives as well as exposure to vinyl-chloride or liver trauma have been considered as influencing factors.⁽¹⁾ Hepatic EHE appears to be a low-grade malignant tumor which progresses slowly. For curative therapy, liver resection (LRx) or liver transplantation (LTx) have been recommended ^(2, 3); however, because of the rarity of this tumor and its unpredictable behavior, it has not been possible to assess the effectiveness of these therapeutic modalities yet.⁽⁴⁾

CASE PRESENTATION

A 56-year-old man presented to us with one episode of severe epigastric pain about five years

before. The pain lasted for almost five hours with no radiation and was subsided without any intervention. The patient had not been exposed to any hepatotoxic drugs and had no important past medical or family history. On admission, physical examination was normal and no hepatosplenomegaly was detected.

In the upper endoscopy, the esophagus and stomach were normal. However, a mild duodenitis was found. Barium meal study detected no abnormality. Among liver function tests, except for a slight increase in alanine aminotransferase (ALT: 45 IU/L), other tests including aspartate aminotransferase (AST), alkaline phosphatase (ALP) and bilirubin (total and direct) were within normal ranges. Markers for viral hepatitis including (hepatitis B surface antigen (HBs-Ag) and (hepatitis C antibody (HCV-Ab) were also negative.

In further evaluation, markers for autoimmune hepatitis including (anti-smooth muscle antibody (ASMA), antinuclear antibody (ANA), and antibodies against liver/kidney microsomes (LKM) were negative. Tumor markers including carcinoembryonic antigen (CEA: 0.7 ng/mL; Normal: up to 2 ng/mL), alpha fetoprotein (AFP: 2 ng/mL; Normal: up to 10 ng/mL), and CA19-9 (9.5 U/mL; Normal: up to 25 U/mL) were also normal.

Moreover, abdominal sonography revealed a 31×31 mm hepatic mass with a hyperechogenic center and a lucent halo in a normal-sized liver. Computed tomography (CT) revealed a cirrhotic liver with degenerative nodules and two hypodense foci (Figure 1). The patient was then referred for laparoscopic liver biopsy (Figure 2, 3) which revealed a diffuse infiltrative tumor encroaches upon the lobules and portal tracts. Histologically, it consisted of cords and tube-like structures and some single tumor cells set in a fibrous hyaline stroma. Tumor cells were plumped to epithelioid, with round to oval nuclei, small nucleoli, and occasional eccentric clear halos or blisters containing red blood cells (RBC).

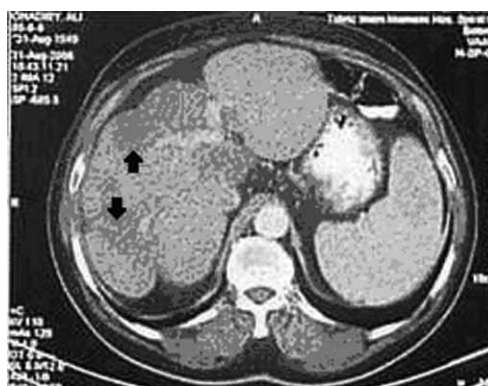


Figure 1. CT showing cirrhotic liver with hypodense foci (arrows)



Figure 2. Hepatic hemangioendothelioma (H&E, ×100): Tumor shows a hyaline stroma, scattered cells and fine vascular lumina. Liver cells are totally lost in this area.

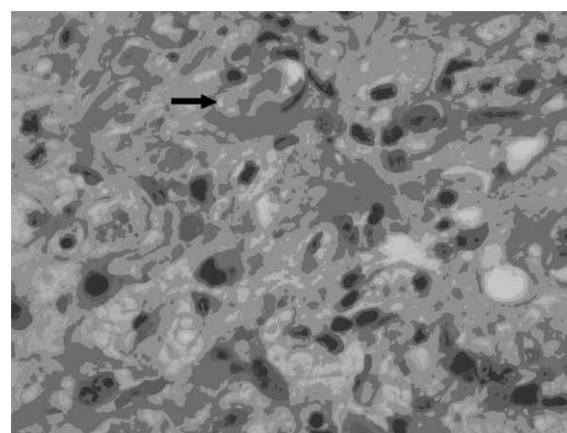


Figure 3. Hepatic hemangioendothelioma (H&E, ×400): Large epithelioid tumor cells are evident, some with intracytoplasmic lumen formation containing red blood cells (arrow).

Trichrome stain revealed regression of the lobules and expansion of tumor stroma more clearly.

Immunohistochemistry stains showed that tumor cells were strongly positive for CD34, weakly positive for CD31, and negative for cytokeratin. Accordingly, the diagnosis of EHE of liver was made and the patient was scheduled for liver transplantation.

DISCUSSION

Hepatic EHE is a rare tumor. It has a vascular origin.⁽¹⁾ This tumor used to be thought as a sclerosing form of cholangio-carcinoma. It has a tendency to present in a multifocal fashion because of its extensive growth along small vessels.⁽⁵⁾ Prevalence of this tumor is higher among women with a female:male ratio of 3:2. ^(6, 7) The mean age of patients has been reported as 46.8 (range: 12-86) years. Additionally, the mean age of patients with hepatic EHE at the time of diagnosis seems to be lower than other hepatic malignancies.⁽⁸⁾

The etiologies of hepatic EHE are still unclear. However, association of hepatic EHE with oral contraceptives has been proposed.^(7, 9) In a previous report, 20% of the patients with hepatic EHE had 17- β estradiol receptors in their lungs.⁽¹⁰⁾ Exposure to vinyl-chloride has also been proposed as a cause.⁽¹¹⁾ In another report, 11% of patients were positive for hepatitis B infection but no correlation was reported between hepatic EHE and hepatitis.⁽⁷⁾

The clinical manifestations and course of EHE of the liver is nonspecific and unpredictable.⁽⁸⁾ Like our case, patients with hepatic EHE may be either asymptomatic ⁽¹²⁾ or present with manifestations of portal hypertension or hepatic failure.⁽¹³⁾ Weight loss and jaundice are common symptoms.⁽⁷⁾ Hepatosplenomegaly is the most common sign. Presence of a liver tumor in young adults, several intrahepatic tumors in a patient with good clinical condition, a slow-growing tumor, or intratumoral calcifications are features that can help us in the diagnosis of hepatic EHE.⁽¹⁴⁾

Laboratory findings seem to be of little use in the diagnosis of hepatic EHE. Raised ALT was the

first laboratory finding in our patient which followed by high AST and ALP. Nonetheless, a raised ALP is generally the most common laboratory finding in hepatic EHE reported in almost 70% of patients. Tumor markers including AFP, CEA and CA 19-9 are within normal range.⁽⁷⁾

Because hepatic EHE usually presents with nonspecific clinical and laboratory manifestations, the diagnosis of hepatic EHE is still only made based on histologic or immunohistochemical methods.^(14, 15) Hepatic EHE has medium- to large-sized cells with epithelioid appearance. These cells typically spread within sinusoids and small veins, forming cell clusters.⁽⁷⁾ The diagnosis is confirmed with immunohistochemical evidence of an endothelial differentiation of tumor, i.e., presence of factor VIII-related antigen and cytokeratins.⁽¹⁴⁾ There is often a characteristic vascular invasion with the tufting of portal vein branches and terminal hepatic venules; the identification of epithelioid and positive dendritic cells for endothelial markers (factor VIII-related antigen, CD34, and CD31); the negative staining for mucin, bile, CEA, or AFP; and the characteristic ultrastructural features such as investing basal lamina, cytoplasmic intermediate filaments, Weibel-Palade bodies, and pinocytotic vesicles. Two main histologic features typically characterize hepatic EHE-the presence of the characteristic dendritic and/or epithelioid cells with evidence of vascular differentiation and identification of intracytoplasmic lumina-containing RBCs. Variable degrees of fibrosis are also observed in all hepatic EHE tumors.⁽³⁾

Two different types of hepatic EHE have so far been described: the "nodular type" and "diffuse type" which may represent "early stage" and "advanced stage" of hepatic EHE, respectively. Vascular invasion including hepatic or portal veins can be seen in the diffuse type.⁽¹⁴⁾ In the early stage, hepatic EHE may appear as discrete or multifocal nodular pattern; later, the lesions may coalesce or present as a diffuse infiltration pattern. Peripheral lesions may lead to hepatic capsular retraction due to extension of disease to the liver capsule and fibrosis. Hypertrophy of other liver segments might also be seen.⁽¹⁶⁾ In the more

common soft tissue counterpart of this tumor, a malignant subtype has been identified that displays atypical features such as cellular atypia, mitotic activity (>1/10 hpf), necrosis or extensive spindling. However, in the liver, only high cellularity and necrosis have been shown to be associated with poor clinical outcome.⁽¹⁷⁾

In addition to intrahepatic tumor presentation, hepatomegaly (46%), splenomegaly (17%), ascites (13%), and portal hypertension (5%) are common radiologic presentations of hepatic EHE.⁽³⁾ CT is the most sensitive imaging method for assessment of tumor's extent. Although the nodular type of hepatic EHE has a rather nonspecific appearance in the CT or magnetic resonance imaging (MRI), the diffuse type is very suggestive for hepatic EHE if the following criteria are fulfilled: a large slow-growing tumor of the liver mainly located in the hepatic periphery without bulging of the liver capsule; peripheral enhancement of contrast; hypervascularized central lesions; a tendency of the tumor nodules to merge into each other; compensatory hypertrophy of liver segments that are not affected; signs of portal hypertension; splenomegaly; and local calcifications.⁽³⁾ As a result of fibrosis, retraction of the adjacent liver capsule may occur.⁽¹⁶⁾ Hepatic calcification may be seen as well. On T1- and T2-weighted MRI, hepatic EHE presents as a hypointense and a hyperintense lesion, respectively. On sonography, the liver may be appeared with discrete nodules or with a diffusely heterogeneous echotexture in regions of extensive diffuse involvement. Echogenicity of individual lesions is variable. Most frequently, the lesions are hypoechoic relative to adjacent hepatic parenchyma, but masses may be hyperechoic or isoechoic relative to background liver.⁽¹⁶⁾ In our patient, the lesion had a hyperechoic pattern with a lucent halo.

Surgical method including liver resection or liver transplantation is the main treatment for hepatic EHE. Other treatment options have also been mentioned including chemotherapy, radiotherapy, and hormone therapy.^(16, 6, 15) Hepatic EHE is multicenter in most of the cases which makes liver resection almost impossible. Therefore, liver transplantation seems to be the best treatment option which leads to a prolonged disease-free

survival. Metastatic spread of hepatic EHE has not been considered a contraindication to surgery.⁽¹⁾ Other treatment options including chemotherapy are not effective.^(18, 2) Interferon α -2b has been used in metastatic cases before or after liver transplantation which may lead to graft rejection.⁽⁶⁾

Extrahepatic tumor spread and morphologic grading or clinical staging of hepatic EHE do not appear to influence the prognosis of hepatic EHE.^(14, 19) One-year survival of hepatic EHE varies from 81.3% (14) to 88% (32); the five-year survival is between 43%-60.2%.^(7, 15)

CONCLUSION

Due to nonspecific clinical and laboratory manifestations of hepatic EHE, the diagnosis can be only made by histologic or immunohistochemical methods. This tumor is resistant to chemotherapy. Therefore, surgical resection or liver transplantation are the most common therapeutic methods available. Studying of more patients is required to establish better and faster diagnostic and therapeutic methods.

References

1. Mucha K, Foronczewicz B, Zieniewicz K, Nyckowski P, Krawczyk M, Cyganek A, *et al.* Patient with liver epithelioid hemangioendothelioma treated by transplantation: 3 years' observation. *Transplant Proc.* 2006; 38: 231-3.
2. Uchimura K, Nakamuta M, Osoegawa M, Takeaki S, Nishi H, Iwamoto H, *et al.* Hepatic epithelioid hemangioendothelioma. *J Clin Gastroenterol.* 2001; 32: 431-4.
3. Mehrabi A, Kashfi A, Schemmer P, Sauer P, Encke J, Fonouni H, *et al.* Surgical treatment of primary hepatic epithelioid hemangioendothelioma. *Transplantation.* 2005; 80: S109-12.
4. Mehrabi A, Kashfi A, Fonouni H, Schemmer P, Schmiel BM, Hallscheidt P, *et al.* Primary malignant hepatic epithelioid hemangioendothelioma: A comprehensive review of the literature with emphasis on the surgical therapy. *Cancer.* 2006; 107: 2108-21.
5. Weiss SW, Enzinger FM. Epithelioid hemangioendothelioma: A vascular tumor often mistaken for a carcinoma. *Cancer* 1982; 50: 970-81.
6. Kayler LK, Merion RM, Arenas JD, Magee JC, Campbell DA, Rudich SM, *et al.* Epithelioid hemangioendothelioma of the liver disseminated to the peritoneum treated with liver transplantation and interferon alpha-2B. *Transplantation* 2002; 74: 128-30.
7. L uffler JM, Zimmermann A, Kr henb hl L, Triller J, Baer

- HU. Epithelioid hemangioendothelioma of the liver. A rare hepatic tumor. *Cancer* 1996; 78: 2318-27.
8. Nagase M, Ryu M, Kinoshita T, Konishi T, Inoue K, Tiku V, *et al.* Epithelioid hemangioendothelioma of the liver. *J Hepatobiliary Pancreat Surg* 2000; 7: 443-7.
 9. Dean PJ, Haggitt RC, O'Hara CJ. Malignant epithelioid hemangioendothelioma of the liver in a young woman. Relationship to oral contraceptive use. *Am J Surg Pathol* 1985; 9: 695-704.
 10. Ohori NP, Yousem SA, Sonmez-Alpan E, Colby TV. Estrogen and progesterone receptors in lymphangiomyomatosis, epithelioid hemangioendothelioma, and sclerosing hemangioma of the lung. *Am J Clin Pathol* 1991; 96: 25-31.
 11. Gelin M, Van de Stadt J, Rickaert F, De Prez C, Levarlet M, Adler M, *et al.* Epithelioid hemangioendothelioma of the liver following contact with vinyl chloride. Recurrence after orthotopic liver transplantation. *J Hepatol* 1989; 8: 99-106.
 12. Ferreira JA, Nuno FJ, Noval J, Palacios J, Alonso P. Hepatic epithelioid hemangioendothelioma: Presentation of a case. *Ann Med Interne* 2000; 17: 446-7.
 13. Rojter S, Villamil FG, Petrovic LM, Silverman JM, Woolf GM, Podesta LG, *et al.* Malignant vascular tumors of the liver presenting as liver failure and portal hypertension. *Liver Transpl Surg* 1995; 1: 156-61.
 14. D'Annibale M, Piovanello P, Carlini P, Del Nonno F, Sciarretta F, Rossi M, *et al.* Epithelioid hemangioendothelioma of the liver: case report and review of the literature. *Transplant Proc* 2002; 34: 1248-51.
 15. Madariaga JR, Marino IR, Karavias DD, Nalesnik MA, Doyle HR, Iwatsuki S, *et al.* Long-term results after liver transplantation for primary hepatic epithelioid hemangioendothelioma. *Ann Surg Oncol* 1995; 2: 483-7.
 16. Lyburn ID, Torreggiani WC, Harris AC, Zwirewich CV, Buckley AR, Davis JE, *et al.* Hepatic epithelioid hemangioendothelioma: sonographic, CT, and MR imaging appearances. *AJR Am J Roentgenol* 2003; 180: 1359-64.
 17. Makhlof HR, Ishak KG, Goodman ZD. Epithelioid hemangioendothelioma of the liver: a clinicopathologic study of 137 cases. *Cancer* 1999; 85: 562-82.
 18. St Peter SD, Moss AA, Huettl EA, Leslie KO, Mulligan DC. Chemoembolization followed by orthotopic liver transplant for epithelioid hemangioendothelioma. *Clin Transplant* 2003; 17: 549-53.
 19. Ben-Haim M, Roayaie S, Ye MQ, Thung SN, Emre S, Fishbein TA, *et al.* Hepatic epithelioid hemangioendothelioma: resection or transplantation, which and when? *Liver Transpl Surg* 1999; 5: 526-31.