

Case Report: Takayasu Arteritis Associated with Ulcerative Colitis

Maryam Mobini¹, Samaneh Hojati²

¹Assistant Professor, Division of Internal Medicine, Imam Khomeini Hospital, Mazandaran University of Medical Sciences, Sari, Iran.

²Researcher, Division of Internal Medicine, Imam Khomeini Hospital, Mazandaran University of Medical Sciences, Sari, Iran.

ABSTRACT

The association of Takayasu arthritis (TA) and inflammatory bowel disease is rare. Early diagnosis and treatment may influence patient survival.

This report describes a 35-year-old woman who had been treated for ulcerative colitis (UC) that manifested with weight loss, upper limb claudication and vertigo. The diagnosis of TA was made according to the American College of Rheumatology criteria. The patient received corticosteroids and cyclophosphamide; however she experienced two additional cerebral events and died after four months. Although the association of TA with UC is rare, we recommend it be considered in young patients with UC who suffer from unexplained weight loss and other constitutional symptoms or cerebrovascular accidents.

Keywords: Takayasu; Ulcerative colitis; Vasculitis

Govaresh/ Vol. 17, No.1, Spring 2012; 60-63

INTRODUCTION

Takayasu arteritis (TA) is a large vessel vasculitis of unknown cause that chiefly affects women during their reproductive years. Chronic inflammation of the vessel wall leads to aneurism formation, stenosis and thrombosis(1).

Ulcerative colitis (UC) is characterized by

Corresponding author:

Maryam Mobini, MD

Assistant Professor, Department of Internal Medicine, Imam Khomeini Hospital, Mazandaran University of Medical Sciences, Sari, Iran

Tel : + 98 151 2261700-4

Fax: + 98 151 2264044

E-mail: mmobini50@yahoo.com

Received : 18 Feb. 2012

Edited : 15 Mar. 2012

Accepted : 17 Mar. 2012

episodes of inflammation of the mucosal layer of the colon. It almost invariably involves the rectum and may extend to proximal portions of the colon. The diagnosis of UC can usually be established by its characteristic history, typical endoscopic appearance of the mucosa and confirmatory histology seen on colonic biopsy(2).

There are some reports about the association of TA and UC. In these reports, patients diagnosed with TA presented with manifestations such as cerebral infarction(3), severe pulsatile headache(4), and severe abdominal pain despite well-controlled UC(5), cervical pain(6), and severe aortic regurgitation(7). Here we have reported the case of a young woman with a two-year history of UC who presented with a cerebrovascular accident. The patient was subsequently diagnosed with TA. Although one report has discussed Crohn's disease and TA in an Iranian patient(8), to the best of our knowledge; this is the first report of an association between UC and TA in Iran.

CSAE REPORT

A 35-year-old woman who had been treated for UC was referred to our hospital with a two month history of weakness in her upper limbs, fatigue, vertigo and diplopia. She was diagnosed with UC by colonoscopy evaluation and biopsy 2 years prior when she complained of chronic bloody diarrhea. The patient was treated with mesalazine (400 mg, bid); despite treatment, she had a 30 kg weight loss since her diagnosis two years prior.

The patient was ill for two months prior to admission with complaints of diplopia and vertigo. Physical examination at the time of admission showed alert consciousness, body temperature of 36.4°C, and regular pulse rate (75 beats/minute), but the blood pressure was not predictable in her upper limbs. Blood pressure in the right lower limb was 140/80 mm Hg. There were no murmurs, rales or abdominal signs. Popliteal and posterior tibialis pulses were palpable. Musculoskeletal system was unremarkable upon physical examination. In the neurologic examination, visual evoked potentials and pupil reflex were absent in the patient's left eye and decreased in her right eye. Romberg test was positive.

Lab data included the following: white blood cell (8400 cells/ μ L), hemoglobin (9.2 g/dl), platelets (573 000 cells/ μ L), erythrocyte sedimentation rate (70 mm/h), positive C-reactive protein, blood urea nitrogen (31 mg/dl), creatinine (1.1mg/dl). Liver enzymes and urine analysis were both normal. Brain MRI with gadolinium showed a large ischemic event in the right occipital lobe (Figure 1). Doppler sonography of her upper limbs demonstrated narrowing of the axillary and brachial arteries with diffuse luminal thickening in the right common carotid and left brachiocephalic arteries. Her angiography was positive for severe narrowing in the carotids and subclavian arteries (Figure 2). The patient was diagnosed with TA according to the American College of Rheumatology criteria. Treatment was begun with high dose of methyl prednisolone as pulse therapy and continued with oral methotrexate and prednisolone. The patient was referred to a cardiac surgeon for vascular surgery but she refused; after two months she experienced a second cerebral attack. This time she received 1 gram methyl prednisolone pulse therapy for three days; cyclophosphamide and high dose prednisolone were continued. The patient died four months after the third cerebral event.

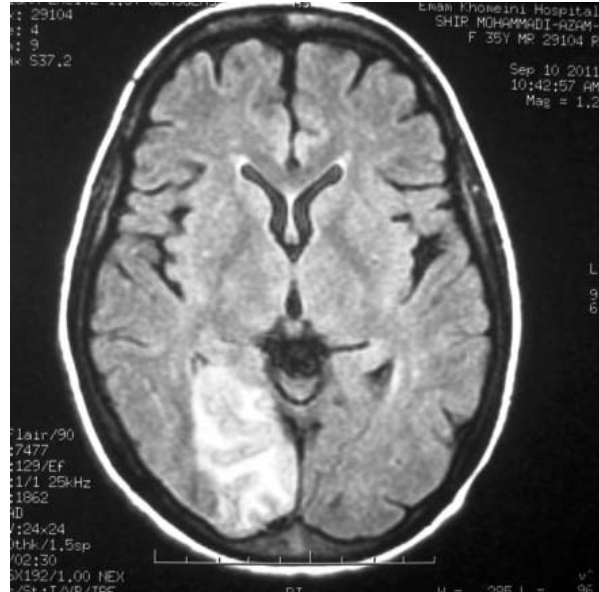


Figure 1: Brain MRI shows a large ischemic event in the right occipital lobe.

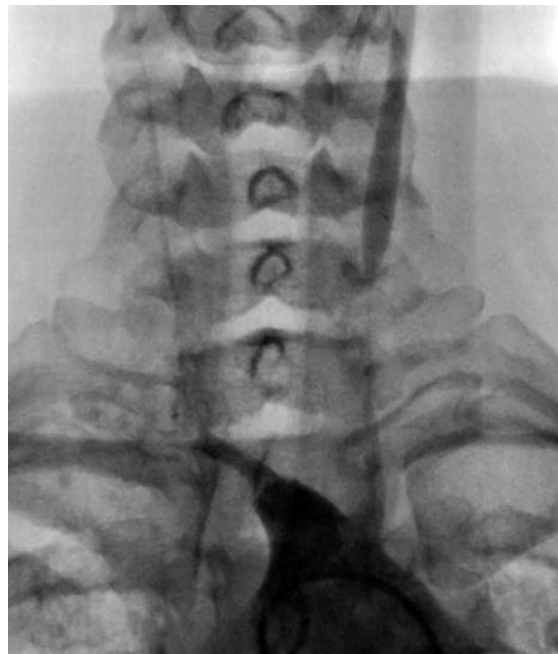


Figure 2: Severe narrowing in the carotids and subclavian as seen on angiography.

DISCUSSION

We presented a case of UC-associated TA with constitutional symptoms and recurrent cerebral events.

Inflammatory bowel disease has been reported with spondyloarthropathies, Sjögren's syndrome, rheumatoid arthritis, inflammatory myopathy and TA(9).TA and UC are chronic inflammatory diseases of unknown etiology, and their coexistence is very rare. The occurrence of the two together is possibly related to a common pathophysiology involving alteration in the immune mechanisms. In patients with both TA and UC, there is a high frequency of HLA-A24, B52 and DR 2(3,6,10).

TA is more prevalent in Japan and Southeast Asia, whereas UC is more common in Western countries(11). Table 1 shows a list of reports about the association between TA and UC. The disorders may begin simultaneously or have a delay of several years. TA may develop after total proctocolectomy for UC(12). The presentation of TA may differ and varies from constitutional symptoms to cerebral or

cardiac manifestations. Abdominal pain, diarrhea, and gastrointestinal hemorrhage may result from mesenteric artery ischemia(13). The presence of constitutional symptoms such as fever, malaise, weight loss, myalgia and ischemic symptoms or signs of one or more large arterial stenoses should raise a suspicion for TA when these features occur in someone under the age of 40 years.

Because of the possibility of an association between these disorders, it is recommended to consider a diagnosis of TA in conjunction with UC in any young patient with UC who suffers from unexplained weight loss, other constitutional symptoms or a cerebrovascular accident. In TA patients, however, there may be a presentation of rectal bleeding and inflammatory colitis due to UC. Full management of these two serious disorders is important because of their potential complications. As the number of cases of UC associated with TD increases, it will be necessary to evaluate their genetic background and possible environmental factors.

Table 1: Examples of the association between ulcerative colitis (UC) and Takayasu arteritis (TA).

Author, year, reference number	Sex	Age at UC diagnosis(years)	Age at TA diagnosis(years)	Clinical significance
Ishikawa et al. 1993 (3)	Female	27	30	After ten years, the patient died of multiple cerebral infarcts
Nomoto et al. 2006 (4)	Female	14	18	Severe pulsatile headache
Balamtekin et al. 2009 (5)	Female	14	15	Severe abdominal pain despite well-controlled UC
Sato et al. 1994 (6)	Female	Before 14	14	Presented with unilateral cervical pain and high fever
Kashima et al. 2010 (7)	Female	Before 25	25	Severe aortic regurgitation
Takahashi et al. 2011 (10)	Male	25	29	Association of TA and UC in a male patient
Shibata et al. 2002 (12)	Female	Before 42	42	Developed TA four months after total colectomy
Morita et al. 1996 (14)	Female	19	23	Developed TA one month after giving birth
Masuda et al. 2002 (15)	Female	41	10	Diagnosed with UC and rectal cancer
Masuda et al. 2002 (15)	Female	20	13	Fulminant UC
Hokama et al. 2003 (16)	Female	Before 36	36	Pulse-less hematochezia
Katsinelos et al. 2005 (17)	Female	37	33	Association of TA and UC in a non- Asian patient
Mobini et al. 2012	Female	33	35	Weight loss, cerebrovascular accident

REFERENCES

- Hellmann DB. Takayasu arteritis. In: Imboden JB, Hellmann DB, Stone JH, editors. *Current Rheumatology Diagnosis and Treatment*. 2nd ed. New York: Lang Medical Books/Mc Graw Hill; 2007. P. 270-5.
- Peppercorn MA. Clinical manifestations, diagnosis, and prognosis of ulcerative colitis in adults. Up to date; version 19.3, 2011.
- Ishikawa H, Kondo Y, Yusa Y, Ejiri Y, Sato Y, Miyata M, et al. An autopsy case of ulcerative colitis associated with Takayasu's disease with a review of 13 Japanese cases. *Gastroenterol Jpn* 1993;28:110-7.
- Nomoto T, Nagao T, Hirabayashi K, Seta T, Yokochi M, Katsura K, et al. Cerebral arteriopathy with extracranial artery involvement in a patient with ulcerative colitis. *J Neurol Sci* 2006;243:87-9.
- Balamtekin N, Gürakan F, Ozen S, Oguz B, Talim B. Ulcerative colitis associated with Takayasu's arteritis in a child. *Acta Paediatr* 2009;98:1368-71.
- Sato R, Sato Y, Ishikawa H, Oshima Y, Suzuki T, Watanabe S, et al. Takayasu's arteritis associated with ulcerative colitis. *Intern med* 1994;33:759-63.
- Kashima K, Kawasaki D, Yotsumoto G, Hatake S, Yamashita E, Nagayoshi S, et al. Rapid progression of aortic regurgitation with thoracic aortic aneurysm due to Takayasu arteritis associated with ulcerative colitis. *Intern Med* 2010;49:1007-11.
- Ebrahimi daryani N, Rafiee MJ, Nayerhabibi A, Bashashati M, Keramati MR. Association of Takayasu's Arteritis and Crohn's Disease: Report of a Case. *Govaresh* 2007;12:98-101.
- Rodríguez-Reyna TS, Martínez-Reyes C, Yamamoto-Furu-sho JK. Rheumatic manifestations of inflammatory bowel disease. *World J Gastroenterol* 2009;15:5517-24.
- Takahashi N, Tanabe K, Sugamori T, Sato M, Kitamura J, sato H, et al. Association between Takayasu arteritis and ulcerative colitis- case report and review of serological HLA analysis. *Med Sci Monit* 2011;17: 81-4.
- Sood A, Midha V, Sood N, bansal M. Coexistence of Takayasu arteritis with ulcerative colitis. *J Assoc Physicians India* 2006;54:151-2.
- Shibata C, Funayama Y, Naito H, Matsuno S, Sasaki I. Takayasu's arteritis after total proctocolectomy for ulcerative colitis: report of a case. *Dis Colon Rectum* 2002;45:422-4.
- Kerr GS, Hallahan CW, Giordanoj, Leavitt RY, Fauci AS, Rottem M, et al. Takayasu arteritis. *Ann Intern Med* 1994;120:919.
- Morita Y, Yamamura M, Suwaki K, Mima A, Ishizu T, Hirohata M, et al. Takayasu's arteritis associated with ulcerative colitis; genetic factors in this association. *Intern Med* 1996;35:574-8.
- Masuda H, Ishii U, Aoki N, Nakayama H, Sato F, Karube H, et al. Ulcerative colitis associated with Takayasu's disease in two patients who received proctocolectomy. *J Gastroenterol* 2002;37:297-302.
- Hokama A, Kinjo F, Arakaki T, Matayoshi R, Yonamine Y, Tomiyama R, et al. Pulseless hematochezia: Takayasu's arteritis associated with ulcerative colitis. *Intern Med* 2003;42:897-8.
- Katsinelos P, Tsolkas P, Beltsis A, Chatzimavroudis G, Papaziogas B, Kapelidis P, et al. Takayasu's arteritis and ulcerative colitis in a young non-Asian woman: a rare association. *Vasa* 2005;34:272-4.