

Autoimmune Hepatitis in Children, Clinical Features and Biochemical of Iranian Children

Mehri Najafi¹, Hamid Reza Kianifar², Seyed Mohammad Mehdi Mir-Nasseri³, Ahmad Khodadad⁴

¹Associate Professor, Tehran University of Medical Sciences, Tehran, Iran

²Assistant professor, Mashad University of Medical Sciences, Mashad, Iran

³Research Fellow, Digestive Disease Research Center, Tehran University of Medical Sciences, Tehran, Iran

⁴Assistant professor, Tehran University of Medical Sciences, Tehran, Iran

ABSTRACT

Background

There are only a very small number of reports which discuss subtype, sex distribution, clinical features and laboratory characteristics of autoimmune hepatitis in children. The aim of this study was both to define the clinical features, biochemical and histological findings and also to determine the age and sex related distribution of autoimmune hepatitis (AIH).

Materials and Methods

Data of 30 children presenting with AIH (20 girls and 10 boys) have been analyzed for their clinical, serological, and histological profile. The most common presenting signs or symptoms were jaundice (60%), abdominal mass (23.4%) and constitutional symptoms (weakness, anorexia and paleness) (6.7%).

Results

About 10% of patients had an acute hepatitis like clinical presentation. Twenty two children (73.3%) (15 girls, 7 boys, 2.1:1) had AIH type 1 and 4 patients (13.3%) type 2 due to specific autoantibodies. Four children could not be classified. In liver biopsy, 100% of patients had interface hepatitis and fibrosis with or without cirrhosis were found in 60%.

Conclusions

In our cohort the prevalence of AIH was 2:1 in girls. Type 1 was the most frequent diagnosis (73.3%) and was more prevalent in older children. Patients with type 2 were younger. The clinical presentation of AIH in children was unspecific and each type could only be differentiated by the determination of the specific autoantibodies.

Keywords: Autoimmune hepatitis type 1, type 2; Children; Autoimmune liver disease

Govaresh/ Vol. 10, No. 2, Summer 2005; 103-107

INTRODUCTION

Autoimmune liver disease in children progress to cirrhosis and liver failure if not diagnosed in time and treated with immunosuppressant.(1-3), This disease usually has an insidious onset and a slow progressive course. Despite viral infections, as possible trigger factors and the frequent presence of some specific HLA allotypes, reflecting a

genetic background, etiology finally remains unknown.(4-6), According to the pattern of detected antibodies two major forms of autoimmune hepatitis are differentiated. Autoantibodies characterizing type 1 are anti-nuclear antibodies (ANA), anti-smooth muscle antibodies (SMA) and anti-soluble liver protein antibodies (SLA). Type 2 is defined by the detection of liver kidney microsomal antibodies (LKM1) and/or liver cytosol 1 antigen (LC1) antibodies.(1), The prerequisite of diagnosis is the exclusion of other known causes of liver disease and the presence of one of the above autoantibodies.

Unfortunately many patients do not reveal

Corresponding author: Children's Hospital Medical Center, Keshavarz Blvd., Tehran, Iran.

Tel: +98 21 88900658

fax: +98 21 8808426

E-mail: mehrinajafi@hotmail.com

significant clinical features at least in an early silent phase of the disease. Thus, it may last for months or years until the final diagnosis has been established, so considerable number of patients is going to present with liver cirrhosis. A number of publications on Autoimmune liver disease have appeared from the Western countries.(7, 8), In Asia these reports are only from Japan and India.(2, 9, 10), In this article clinical features and biochemical data of children with autoimmune liver disease in our hospital (Children Medical Center Hospital) will be discussed.

MATERIALS AND METHODS

Between 2001 to 2003, In a cohort study, 30 children with the diagnosis of autoimmune hepatitis in Children Medical Center Hospital related to Tehran University of Medical Sciences were prospectively enrolled in the study.

Investigations of liver function tests (LFT), prothrombin time (PT), ultrasonography of the abdomen, upper gastrointestinal endoscopy, liver biopsy (whenever feasible), hepatitis B surface antigen, hepatitis C antibody (if antibody tested positive further confirmed by HCV-RNA), and work-up for Wilson's disease serum ceruloplasmin, 24 h urinary copper, D- penicillamine challenge and Keyser-Fleicher ring) and alpha-1-antitrypsin deficiency were done. In patients with acute hepatitis like, IgM hepatitis A was done.

Autoimmune markers ANA, SMA and anti-LKM1 were tested by using indirect immunofluorescence in all cases.

Autoimmune liver disease was diagnosed when one or more of the autoantibodies (ANA, SMA, and anti LKM-1) tested positive (titers for each antibody > 1:40), and no other known cause of liver disease was identified. Furthermore, all patients had elevated serum gama globulin and liver biopsy findings compatible with autoimmune hepatitis. We also applied criteria proposed by the International Autoimmune Hepatitis Group (IAIHG) to define autoimmune etiology in our patients.(11), In a questionnaire, data on demographic patient characteristics, presented clinical signs and symptoms, biochemical and histological findings were collected. We also used the modified HAI (Ishak) scoring system to cover grade and stage. In this scoring grading (1-18) and staging (0-6) determine the severity of the disease.(12), The protocol was approved by the ethics committee of the university. The parents gave informed consent.

RESULTS

Analysis of data from 30 patient with autoimmune hepatitis revealed that 20 patients were female and 10 were male, aging from 2.5 to 14 years (mean age 8.07 years). The age distribution at the time of diagnosis also stratified by gender and AIH type is reported in Figure 1.

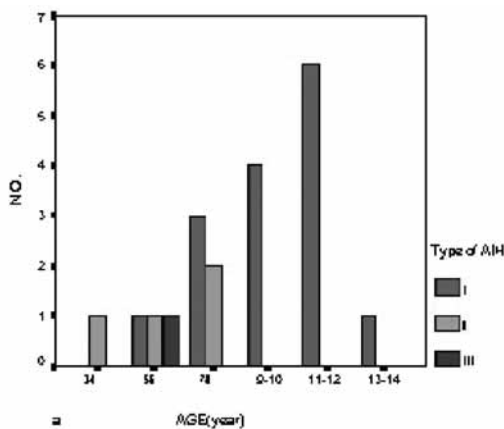


Figure 1 (a): Frequency of AIH in relation to age, and AIH type in female (20 patients). CCH; Cryptogenic Chronic Hepatitis

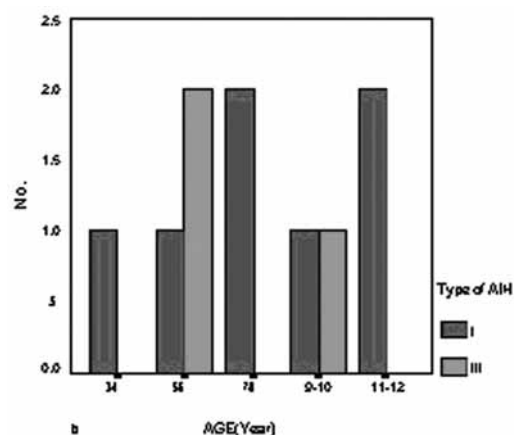


Figure 1 (b): Frequency of AIH in relation to age and AIH type in male (10 patients). CCH; cryptogenic chronic hepatitis

None of these cases had a history of blood transfusion, surgery or intake of hepatotoxic drugs. Jaundice was present in 18 (60%), and it represented the most consistent finding. Three cases (10%) had acute hepatitis like clinical presentation with jaundice, having a duration of less than three 3 months. In 23.4% abdominal mass (organomegaly) and in 6.7% constitutional symptoms such as anorexia, fatigue or weight loss or pallor was the first presenting signs and symptoms. None of patients had fulminant hepatitis or encephalopathy as a chief complaint. Duration of symptoms was more than 3 months in 90% of cases.

We revealed hepatomegaly in 26 (86.7%), splenomegaly in 24 (80%), clubbing in 11 (36.6%), ascites in 6 (20%) and failure to thrive in 4 (13.3%).

There were 2 cases with ulcerative colitis and 1 with alopecia in type 1 group and 1 patient with insulin dependent diabetes in type 2 of disease. In one of 2 patients with ulcerative colitis, her father also had the same colon disease.

Anti-nuclear antibodies, anti-smooth muscle antibodies corresponding to AIH type 1 were detected in 22 children (73.3%) (15 girls, 7 boys, 2.1:1). SMA were exclusively present in 15 children (50%) (9 girls, 6 boys, 1.5:1), ANA in 5 (16.7%). Only 2 (6.7%) had positive SMA and ANA simultaneously. Anti-liver kidney

microsomal antibodies characterizing AIH type 2 were detected in 4 patients (13.3%) which all of them were female. Details are shown in Table 1. Upper gastrointestinal endoscopy was normal, except 4 patients, who had esophageal varices. In 4 children (13.3%) no autoimmune antibodies could be identified despite characteristic clinical and histological findings. The distribution of type 1 and 2 in dependence on age (Figure 1) showed clearly that the prevalence of AIH type 1 increased markedly beyond the age of 9-10 years.

Table 1. Autoantibodies in 30 children with AIH

Autoantibody	Girls	Boys	Total
Type I	15	7	22 (73.3%)
SMA	9	6	15
ANA	4	1	5
ANA+SMA	2	0	2
Type II			
LKM	4	0	4 (13.3%)
(CCH)	4	0	4 (13.3%)

The laboratory findings in AIH were unspecific. However, the globulin levels, if significantly elevated, represented a strong marker of suspicion. Data are shown in Table 2.

Histological exploration of 24 children revealed mean of 5.7 (2-11) for HAI grading and 3.7 (0-6) for stage. Interface hepatitis was seen in 100% and

Table 2. Laboratory findings in AIH type 1, type 2 and CCH; Cryptogenic chronic hepatitis

type	ALT* (U/l)	AST* (U/l)	T.bili* (mg/dl)	D.bili* (mg/dl)	PT* (sec)*	T.protein* (g/dl)	Globulin* (g/dl)	Alkp* (U/l)	Hgb* (g/dl)	Plt* (count/mm ³)
I	556.4 (640.1)	714.9 (847)	6.7 (7.6)	4.7 (5.9)	15.9 (3.9)	8.1 (1.3)	4.2 (1.06)	722 (482)	10.9 (1.5)	155×10 ³ (85×10 ³)
II	270.7 (81.4)	300.7 (68.4)	5.4 (3.3)	3.5 (2.4)	19.4 (4.4)	7.5 (.68)	3.9 (.15)	1009 (131)	10.1 (2.3)	259×10 ³ (185×10 ³)
(CCH)	267.2 (218.8)	263 (122)	2.9 (2.7)	1.8 (1.7)	13.8 (1.2)	7.1 (.43)	3.1 (.12)	797 (556)	11.6 (1.1)	189×10 ³ (459×10 ³)
Total	479.7 (564.9)	599.3 (748)	6 (6.7)	4.1 (5.2)	16.1 (3.9)	7.9 (1.2)	4.06 (.98)	772 (459)	10.9 (1.6)	176×10 ³ (103×10 ³)

fibrosis+/- cirrhosis was found in 60%. 9(40.9%) patients with type 1, and 3(75%) of type 2 had cirrhosis. Of these 4 of type 1 and 2 of type 2 had Child C.

Data of histological scoring in each type of disease are shown in table 3.

Table 3. Histological staging and grading of types of AIH

GROUP	Grade	Stage
I Mean(SD)	5.7 (2.4)	3.6 (2.1)
II Mean (SD)	6 (2.6)	5 (1)
(CCH) Mean (SD)	5.3 (3.5)	3 (2.6)
Total Mean (SD)	5.7 (2.4)	3.7 (2)

DISCUSSION

Autoimmune liver disease is one of the most important causes of chronic liver disease in children. Its prevalence differ in different parts of the world. In North America and Western Europe it accounts for about 20% of chronic hepatitis cases(13), but it accounted for only 3.9% chronic liver disease in India.(2), Autoimmune liver disease has been described to have a female preponderance.(13), This ratio is about 4:1 in some reports(13, 14, 15, 16) and almost equally distributed prevalence in the United states. In our study the overall female/male ratio was 2:1. Disease predominance in female is depending on the type of AIH, in our study all of 4 patients with type 2 were female.

The disease was spread over all age groups with slight peaks at 7, 11 and 14 years. Patients with type 2 seem to be younger with higher bilirubin levels and a higher inflammatory activity. In Porta *et al.* study children with type 1 AIH were older at onset (mean age 8 vs. 3 years) and Gregorio *et al.* study reported a mean age of 10 years for type 1 and 7 years for type 2, and in Oettinger *et al.* study

also mean age of 11.5 years versus 9 years reported for type 1 and 2, respectively.(8, 17, 18), In our patients type 1 showed an increasing incidence with age (mean age 9.2 years) whereas the incidence of type 2 (mean age 5.6 years) was independent of age.

In accordance with previous studies there were no particular clinical signs, symptoms, or liver test abnormalities of sufficient specificity to be considered as a reliable part of diagnostic criteria.(11), The onset was usually uncharacteristic, with fluctuating jaundice, weakness, anorexia and abdominal pain as typical features, but a considerable number of patients had no obvious signs or symptoms of liver disease at all. Like our patients (60%), in three independent study 63%, 56% and 57.7% of reported patients had jaundice at presentation.(8, 15-17), In the Porta *et al.* report the majority (82%) had symptoms of acute hepatitis at presentation.(18)

In our study globulin concentrations in type 1 were higher, probably as an indicator for an immunologically more active disease. In our group of 30 children 73.3% presented with significant titres of ANA and/or SMA, and 13.3% had anti-LKM1 antibodies. In several studies range of 62% to 92% for type 1 and 8% to 38% for type 2 have been reported.(8,15-18), The characteristic histological picture is interface (periportal or preseptal) hepatitis with lymphoplasmatic necroinflammatory infiltrate, with or without lobular (intra-acinar) involvement, porto-portal or central-portal bridging necrosis with formation of liver cell rosettes and a great amount of plasmatic cells at an early stage of the disease.(18), There is evidence that liver cirrhosis in initial biopsy is more frequent in type 1 than in type 2. Cirrhosis was reported in range of less than half to more than 90% of affected children.(8, 15, 17, 18), In our study histological exploration of 24 children revealed interface hepatitis in 100% and fibrosis with or without cirrhosis in 60%. Hepatitis and cirrhosis were more common in AIH type 2.

Recently IAIHG has proposed a scoring system

for uniformity in the diagnosis of autoimmune hepatitis.(11), 26 patients of our patients had definite (score > 15) and 4 had probable (score 10-15), or cryptogenic chronic hepatitis. None of our patients had a score below 10 which is very specific for exclusion of AIH.

If AIH remains untreated, progression to liver cirrhosis with consecutive liver failure is usually inevitable. The standard treatment in our collective was prednisone in combination with azathioprin. Only 4 patients with with CCH (cryptogenic chronic hepatitis) (13.3%) received the steroid alone. Twenty six children received combined treatment with corticosteroids and azathioprin.

Our data revealed, AIH type 1 was the predominant form of autoimmune hepatitis in our children. The number of patients diagnosed increase with age, particularly in type 1. Boys were affected half as much as girls by type 1. Jaundice is the most common presentation of disease, which seen in acute hepatitis, Therefore, autoimmune liver disease should be considered as a differential diagnosis.

Early diagnosis and treatment of disease may decrease histological features of cirrhosis and could prolong the survey.

ACKNOWLEDGMENTS

During the first 3 years the study was supported by a grant from the Conceal of Research, Tehran University of Medical Sciences, and authors would like to thank them for offering us the grant to finance this work.

References

- Obermayer-Straub P, Strassburg CP, Manns MP. Autoimmune hepatitis. *J Hepatol* 2000; 32: 181-97.
- Yachha SK, Srivastava A, Chetri K, Saraswat VA, Krishnani N. Autoimmune Liver Disease In Children. *Journal of Gastroenterology and Hepatology* 2001; 16: 674-7.
- Maggiore G, Bernard O, Hadchouel M, Hadchouel P, Odievre M, Alagille D. Treatment of autoimmune chronic active hepatitis in childhood. *J Pediatr* 1984; 104: 839-44.
- Vento S, Garofano T, di Perri G, Dolei L, Conita E, Basetti D. Identification of hepatitis A virus as a trigger for autoimmune chronic hepatitis type 1 in susceptible individuals. *Lancet* 1991; 337: 1183-7.
- Vento S, Guella L, Mirandola F, Cainelli F, Di Perri G, Ferraro T, et al. Epstein-Barr virus as a trigger for autoimmune hepatitis in susceptible individuals. *Lancet* 1995; 346: 608-9.
- Schmitt K, Deutsch J, Tulzer G, Meindi R, Aberle S. Autoimmune hepatitis and adrenal insufficiency in an infant with human herpesvirus-6 infection. *Lancet* 1996; 348: 966.
- Maggiore G, Veber F, Bernard O, Hadchouel M, Homberg JC, Alvarez F, et al. Autoimmune hepatitis with antiactin antibodies in children and adolescents. *J Pediatr Gastroenterol Nutr* 1993; 17: 376-81.
- Oettinger R, Brunnberg A, Gerner P, Wintermeyer P, Jenke A, Wirth S. Clinical features and biochemical data of Caucasian children at diagnosis of autoimmune hepatitis. *Journal of Autoimmunity* 2005; 24: 79-84.
- Omagari K, Kinoshita H, Kato Y, Nakata K, Kanematsu T, Kusumoto Y, et al. Clinical features of 89 patients with autoimmune hepatitis in Nagasaki Prefecture, Japan. *J Gastroenterol* 1999; 34: 221-6.
- Toda G, Zeniya M, Watanabe F, Imawari M, Kiyosawa K, Nishioka M, et al. Present status of autoimmune hepatitis in Japan--correlating the characteristics with international criteria in an area with a high rate of HCV infection. Japanese National Study Group of Autoimmune Hepatitis. *J Hepatol* 1997; 26: 1207-12.
- Alvarez F, Berg PA, Bianchi FB, Bianchi L, Burroughs AK, Cancado EL, et al. International autoimmune hepatitis group report: Review of criteria for diagnosis of autoimmune hepatitis. *J Hepatol* 1999; 31: 929-38. No abstract available.
- Ishak K, Baptista A, Bianchi L, et al. Histologic grading and staging of chronic hepatitis. *J Hepatol* 1995; 22: 696.
- Manns M, Strassburg C. Autoimmune hepatitis: Clinical challenges. *Gastroenterol* 2001; 1502-17.
- Mieli-Vergani G, Vergani D. Autoimmune liver disease. *Indian J Pediatr* 2002; 69: 93-8.
- Badia I, Ferro A, Galoppa C, Carabajal P, De Matteo E, Marco I. Autoimmune hepatitis type 1: experience with 107 pediatric patients. *J Pediatr Gastroenterol Nutr* 2000; 31(Suppl 2): S203.
- Celli A, Harmsen S, Therneau T, Perrault J, El-Youssef M, Freese D. Autoimmune hepatitis in childhood e 14 years review. *J Pediatr Gastroenterol Nutr* 2000; 31(Suppl 2): S203.
- Gregorio GV, Portmann B, Reid F, Donaldson PT, Doherty DG, McCartney M, et al. Autoimmune hepatitis in childhood: A 20-year experience. *Hepatology* 1997; 25(3): 541-7.
- Porta G, Miura IK, Cardoso RA, Bittencourt PL, Vianna R, Pugliese RPS, et al. Clinical and laboratory features of Brazilian children with autoimmune hepatitis types 1 and 2. *J Pediatr Gastroenterol Nutr* 2000; 31(Suppl 2): S4.
- Baranov AA, Kaganov BS, Gundobina OS, Zainudinov ZM. Autoimmune Hepatitis in Children. *International Pediatrics* 2003; 18(1): 23-9.