

Extracolonic Manifestations in Familial Adenomatous Polyposis

Narimantas Evaldas Samalavicius*

Department of Surgery, Vilnius Center University Hospital, Vilnius, Lithuania

ABSTRACT

Introduction

Due to the whole network of polyposis registers worldwide and early prophylactic treatment, survival of familial adenomatosis (FAP) patients is improved. Extracolonic manifestations are remarkable feature of FAP. Two extracolonic manifestations (duodenal adenomatosis, leading duodenal cancer and desmoid tumours) play a very important role in the reasons of death in polyposis population.

Materials and methods

Data from the Lithuanian Polyposis Register, containing 90 FAP cases from 38 unrelated families (as stated on 2004.01.01) was used. Indirect ophthalmoscopy (fundoscopy) was performed on 19 FAP patients, orthopantomography - on 22, upper gastrointestinal tract endoscopy on 21, distal small bowel examined in 11. 42 patients were examined for desmoid tumours and epidermoid cysts.

Results

In 18 (94.7%) of 19 examined CHRPE was detected, in 15 (68.2%) of 22 -mandibular osteomas. Out of 21 examined, 3 (14.3%) had fundic gland polyposis and 14 (66.7%) duodenal adenomas. Distal ileal polyposis was present in 8 (72.7%) of the 11 patients. Out of 42 live FAP patients, 4 (7.1%) had desmoid tumours and 8 (14.3%) had epidermoid cysts.

Conclusions

Extracolonic manifestations are typical in FAP. Some of them have negative impact on morbidity and mortality of FAP patients and demand special surveillance and treatment. *Govaresh 2003; 8: 178-83*

Keywords: familial adenomatous polyposis, extracolonic manifestations, incidence

INTRODUCTION

Familial adenomatous polyposis (FAP) is a disease inherited in an autosomal dominant fashion, which due to a mutation on chromosome five results in the development of up to several thousands of colorectal adenomas and a number of extracolonic manifestations. All untreated patients develop colorectal cancer. If there are no systematic attempts to approach this disease, all responsibility has to be taken by a doctor, who incidentally diagnoses FAP. This has been proven to be inadequate in the control of this disease, as whenever contact with the FAP family is lost, the

possibility of the diagnosis of colorectal cancer is more likely than the diagnosis of FAP itself and early prophylactic treatment. Although in up to 40 percent of patients FAP could be caused by a spontaneous mutations⁽¹⁻³⁾, at least in the remaining 60 percent the possibility of colorectal cancer could be diminished to zero. The first FAP register was started by Lockhart-Mummery P in 1925⁽⁴⁾, and today a whole network of FAP registers exists worldwide.

Polyposis register in Lithuania has been established in 1995, and up till now it remains the only national register for FAP in Eastern Europe and states of former Soviet Union. At the moment (by 1st January, 2004), Lithuanian Polyposis Register contains information on 90 FAP cases from 38 unrelated families.

Due to the whole network of polyposis registers worldwide and early prophylactic treatment, survival of familial adenomatosis patients is

*Corresponding author: Narimantas Evaldas Samalavicius MD, PhD, Chief of Colorectal Unit, Department of Surgery, Vilnius Center University Hospital, Zygimantu 3, 2001 Vilnius, Lithuania.
E-mail: narimantsam@takas.lt

improved. In turn, several extracolonic manifestations (as duodenal adenomatosis, leading to duodenal cancer and desmoid tumours) play a very important role in the reasons of death in polyposis population.

This article evaluates extracolonic expression of familial adenomatous polyposis, based on the data of the Lithuanian Polyposis Register.

MATERIALS AND METHODS

Indirect ophthalmoscopy (fundoscopy) was performed on 19 FAP patients: 7 men and 12 women, age range 15 - 50 years with an average of 30 years. A control group included 100 unselected controls, 64 men and 36 women, age range 18 - 58 years with an average of 35 years, who underwent the same examination for prophylactic purposes. All patients were examined by the same ophthalmologist.

Orthopantomography was performed on 22 FAP patients, 13 women and 9 men, age range 15-50 years with an average of 30 years. A control group included 100 unselected controls, 83 men and 17 women, age range 7 - 67 years with an average of 32 years, who underwent the same examination because of trauma (most) or for other reasons. All orthopantomograms were evaluated by the same radiologist.

Upper gastrointestinal endoscopy was performed on 21 FAP patients, 9 women and 12 men, age range 15-50 years with an average of 31 years. A control group included 3,700 unselected patients, who underwent the same examination due to other disorders in the same period. All patients were examined by one endoscopist (N.E.S.).

Examination of the terminal part of the small bowel (ileum) was performed on 11 patients (methods: colonoscopy with distal ileoscopy, surveillance after subtotal colectomy and ileorectal anastomosis or removal of distal part of ileum surgically with the right part of colon), 7 women and 4 men, age range 16 - 45 years with an average of 32 years.

42 live patients were examined for desmoid tumours and epidermoid cysts. Examination included anamnesis and physical examination, followed (for desmoids) by abdominal sonoscopy and computer tomography as well as histological confirmation when possible.

RESULTS

Congenital hypertrophy of retinal pigment epithelium (CHRPE). 19 patients were examined using indirect ophthalmoscopy, and in 18 (94.7%) CHRPE was detected (Figure 1). The number of these lesions varied from 1 to 14 with an average of 6.1. In all cases these lesions were bilateral, and in no patients were they single in both eyes. Sizes varied from minute to a little larger than one optic disc diameter (DD); most were 1/3 DD. None of the 100 controls had CHRPE.

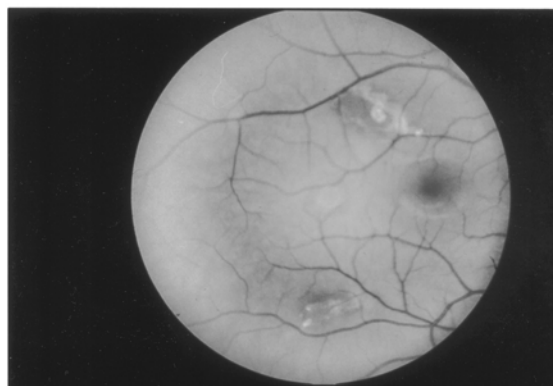


Figure 1: Congenital hypertrophy of the retinal pigment epithelium in a 25 year old male FAP patient.

Mandibular osteomas. Orthopantomography was performed on 22 FAP patients and 100 unselected controls. In 15 (68.2%) FAP patients (Figure 2) and three (3%) controls mandibular osteomas were detected (difference statistically significant: OR=22.73, confidence intervals 5.48-109.07; P<0.001). In FAP osteomas numbered from one to seven with an average of 2.7 per FAP patient. In controls all lesions were solitary. In only 6 (40%) of FAP patients with osteomas these lesions were solitary. Size varied from 2 to 12 mm with an average of 5 mm.

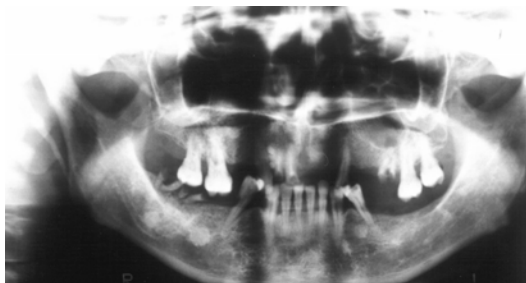

Figure 2: Multiple mandibular osteomas seen on orthopantomography in a 24 year old male FAP patient.

Gastroduodenal polyps. Upper gastrointestinal endoscopy was performed on 21 FAP patients. Only in 3 (14.3%) fundic gland polyposis was detected (Figure 3). In one (4.8%) patient gastric adenoma was detected and endoscopically removed. The number of gastric adenomas was compared to findings in 3,700 controls, where in 42 (1.1%) adenomas were detected and no statistically significant difference was found [OR=4.2, P=0.13 (Fisher Test), P>0.2].

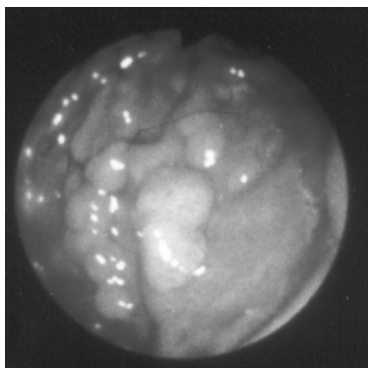


Figure 3: Endoscopic view on multiple fundic gland polyps in a 32 year old FAP female patient.

Duodenal adenomas were detected in 14 (66.7%) patients (Figure 4); they varied in size from 1 to 6 mm and numbered between 4 and 50; histologically - tubular adenomas.

Duodenal adenomatosis was classified according to Spigelman classification, and is illustrated in the Table.

Table. Duodenal adenomatosis according to Spigelman

Stage	Number of patients (%)
I	7 (50%)
II	5 (35.7%)
III	2 (14.3%)
IV	0

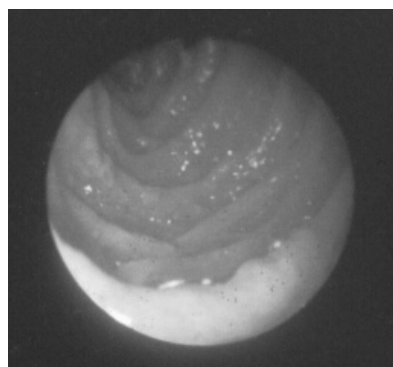


Figure 4: Endoscopic view on Spigelman I type duodenal polyposis in a 22 year old FAP female patient.

Distal ileal polyps. Distal ileal polyps were detected in 8 (72.7%) of the 11 examined patients (Figure 5): adenomas in 4 (36.4%), lymphoid hyperplasia in 3 (27.3%) and mixed polyposis in 1 (9.1%).

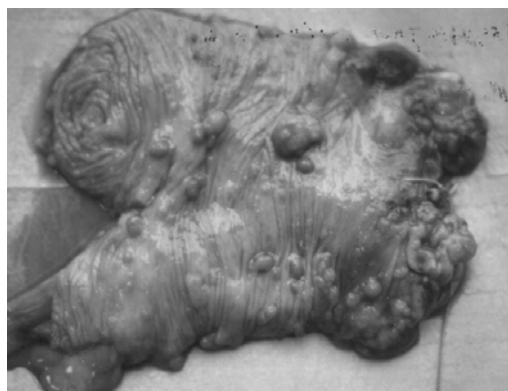

Figure 5: Surgical specimen of a distal ileal and caecal segment removed in a 48 year old FAP female after previous subtotal colectomy and caecostomy: multiple distal ileal adenomas are visible.

Desmoid tumours. Desmoid tumours have been detected in 4 (7,1%) out of 42 examined patients (3 female, 1 male, age 22, 21, 28 and 36) (Figure 6): two in the abdominal wall, and two intraabdominal. Both patients for abdominal wall tumours were successfully treated with Sulindak and tamoxifen. One patient for intraabdominal desmoid was operated on as an emergency case for bowel obstruction, a short small bowel (jejunum) segment and 5 × 6 × 8 cm desmoid tumour located in small bowel mesentery were removed (no recurrence in 18 months). One patient with large multiple abdominal wall tumours up to 12-14 cm in diameter

did not respond to Sulindac and tamoxifen, later cytostatics and radiotherapy as well did not show benefits, and he is under observation and treatment at the moment. Histology was confirmed in two (with intraabdominal desmoids) of 4 patients with desmoids (postoperative specimen in one, needle biopsy in another).

Epidermoid cysts were detected by inspection alone or as well history of being removed in 6 (14.3%) of 42 examined patients (Figure 7).

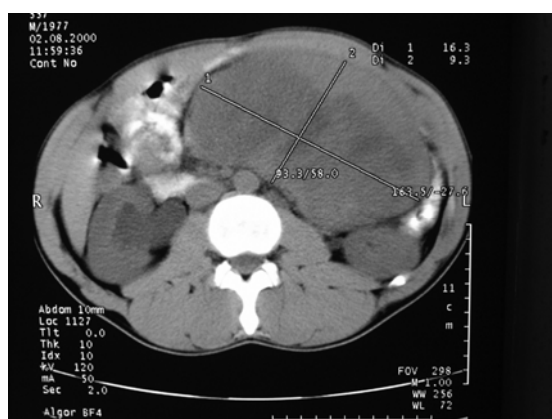

Figure 6: CT scan on a large intraabdominal desmoid tumour in a 24 year old FAP male patient, which occurred 1 year after prophylactic subtotal colectomy.

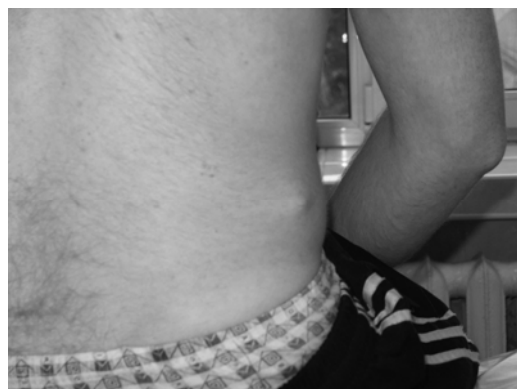

Figure 7: Epidermoid cysts in a 34 year old FAP patient: patient history revealed another over 10 epidermoid cysts previously removed.

DISCUSSION

One or more extracolonic manifestation was present in a majority of our patients.

CHRPE was first described in sporadic cases by Reese AB and Jones IS⁽⁵⁾; these patients had no

other underlying diseases. And it was noted, that in such cases lesions are as a rule solitary. Even though we did not find any CHRPE in a control group, Lyons LA⁽⁶⁾ noted CHRPE to be present in 1 out of 50 in a general population. Solitary lesions were present only in one eye in 3 of our patients. In all of these patients, multiple lesions were noted in the other eye. Size of the CHRPE in our study group was in accordance to other authors⁽⁷⁻¹⁰⁾ – most of them were up to one optic disc diameter, and only few little larger. There are reports, that if both CHRPE and mandibular osteoma are present in an asymptomatic first degree relative to a FAP patient, FAP should be strongly suspected⁽¹¹⁾.

In 15 (68.2%) out of 22 FAP patients and in 3 (3%) out of 100 unselected controls mandibular osteomas were detected. This significant difference emphasises the importance of this lesion in FAP population. Both the percentage of FAP patients and healthy controls with osteoma are in accordance with other studies⁽¹²⁻¹⁹⁾. We applied Kubo K⁽²⁰⁾ criteria for evaluation of osteomas on orthopantomography. Both size and number of osteomas is similar to previous reports^(12,17). It is important to note, that in FAP patients osteomas were multiple (on an average 2.7 osteoma per patient), and exactly multiple mandibular osteomas are distinct feature of FAP. Fundic gland polyposis has been detected only in 14.3% of patients. This percentage is much less then usually described – up to a half of FAP patients have this cystic dilation of the gastric fundal glands^(21,22). This feature is extremely related to FAP: only one report from Iida M in 1984⁽²³⁾ diagnosed fundic gland polyposis in 0.085% of examined non-FAP patients. Gastric polyps in FAP show no distinction compared to general population. The different situation is with duodenal polyposis. It has been first reported in 1935⁽²⁴⁾. Prophylactic screening for FAP and early colectomy increased survival of polyposis patients worldwide, and patterns of mortality changed. Duodenal cancer today is one of the major causes of death of FAP patients⁽²⁵⁾. In 1989, Spigelman AD with co-authors⁽²⁶⁾ published a classification of duodenal polyposis, based on endoscopical and histological criteria, which now is very widely applied. The main

attention in this classification is concentrated to polyp number, size of the polyps, histological type of adenoma (tubular, villous), and level of dysplasia: larger polyps and bigger in number, with villous changes and severe dysplasia would mean large stage. Spigelman stage I or II would probably demand surveillance alone, stage III is likely to necessitate medical or endoscopic treatment, and stage IV – often surgical approach. We detected duodenal adenomatosis in 66.7% of our patients, and that is very much in accordance with recent, largest and most important to date report from Nordic registries and the Netherlands, where duodenal adenomatosis was detected in 65%⁽²⁷⁾. We had no cases of duodenal cancer – and none of our patients had Spigelman IV stage. This is very likely to be related with the average young age of our patients (average -31 year). It's as well obvious, that duodenal cancer is likely to develop from Spigelman stage IV duodenal polyposis: 4 out of 11 developed duodenal cancer in St. Marks study⁽²⁸⁾, 3 of 11 in Swedish study⁽²⁹⁾ and 2 of 26 in Nordic/Netherlands study⁽²⁷⁾.

Small intestinal involvement in FAP did not get much attention until recently. Ohsato et al in 1977⁽³⁰⁾ was first to try to evaluate systematically small bowel status. Further reports determined, that ileal polyps are present in most of the patients with FAP, either determined during intraoperative enteroscopy⁽³¹⁾ or after ileoproctostomy⁽³²⁾. We detected ileal polyps in two thirds of our patients. Even though aggressive adenomatous changes are reported in terminal ileum^(33, 34) and risks of malignant transformation is encountered⁽³⁵⁾, true risk of developing small bowel cancer, as well as appropriate schemes of surveillance and treatment are yet to be determined.

Desmoid tumours is second very important expression of FAP. To date, it is another of most frequent reasons of death of polyposis patients. These tumours do not metastasize, but quite often cause a lot of problems due to local invasive growth. We detected desmoid tumours in 7.1% of FAP patients, and that is about the average reported by the major series⁽³⁶⁻⁴⁰⁾. The only study reporting 14% of FAP patients developing desmoids comes from Finland⁽⁴¹⁾. Surgery for desmoid disease usually leads to large resection,

and recurrence is often. Role of radiotherapy is minute. Cytostatics might be of help, but the front line treatment of desmoid disease today is a combination of antiestrogenic drug (e.g. tamoxifen) and anti-inflammatory medicine (Sulindac)^(38,41,42).

Reports concerning incidence of epidermoid cysts in FAP are very variable: British report of 39 (53%) of 74⁽⁴³⁾ having epidermoid cysts is in contrast to 8 (3%) of 243 in Danish series⁽³⁾. We detected 14.3% FAP patients having multiple epidermoid cysts, and it is more in accordance with the Danish data.

Extracolonic manifestations are typical in FAP. Some of them have negative impact on morbidity and mortality of FAP patients and demand special surveillance and treatment.

References

1. Bussey HJR. Familial polyposis coli. Family studies, histopathology, differential diagnosis and results of treatment. Baltimore: John Hopkins University Press; 1975.
2. Utsonomiya J, Iwama T. Adenomatosis coli in Japan. In: Winawer S, Schottenfeld D, Sherlock P, editors. Colorectal cancer: Prevention, epidemiology and screening. New York: Raven Press; 1980.
3. Bullow S. Familial polyposis coli. A clinical and epidemiological study. Thesis. *Dan Med Bull* 1987; **34**: 1-15.
4. Lockhart-Mummery P. Cancer and heredity. *Lancet* 1925; **I**: 427-9.
5. Reese AB, Jones IS. Benign melanomas of the retinal pigment epithelium. *Am J Ophthalmol* 1956; **42**: 207-12.
6. Lyons LA, Lewis RA, Strong LC *et al*. A genetic study of Gardners syndrome and retinal pigment epithelium. *Am J Hum Genet* 1988; **42**: 290-6.
7. Traboulsi EI, Krush AJ, Gardner EJ *et al*. Prevalence and importance of pigmented ocular lesions in Gardners syndrome. *N Engl J Med* 1987; **3**: 661-7.
8. Berk T, Cohen Z, McLeod RS *et al*. Congenital hypertrophy of retinal pigment epithelium as a marker for familial adenomatous polyposis. *Dis Colon Rectum* 1988; **31**: 253-7.
9. Chapman PD, Church W, Burn J *et al*. Congenital hypertrophy of retinal pigment epithelium: a sign of familial adenomatous polyposis. *BMJ* 1989; **298**: 353-4.
10. Moore AT, Maher ER, Koch DJ. Incidence and significance of congenital hypertrophy of retinal pigment epithelium (CHRPE) in familial adenomatous polyposis coli (FAPC). *Ophthalmol Paediatr Genet* 1992; **13**: 67-71.

11. Giardello FM, Offerhaus GE, Traboulsi EI *et al.* Value of combined phenotypic markers in indentifying inheritance of familial adenomatous polyposis. *Gut* 1991; **32**: 1170-4.
12. Utsonomiya JJ, Nakamura T. The occult osteomatous changes in mandible in patients with familial adenomatous polyposis coli. *Br J Surg* 1975; **62**: 45-51.
13. Ushio K, Sasagawa M, Doi H *et al.* Lesions associated with familial adenomatous polyposis coli: studies of the lesions in the stomach, duodenum, bones and teeth. *Gastrointestinal Radiol* 1976; **1**: 67-80.
14. Shoji K, Watanabe H, Goto Y *et al.* Morbid changes in mandible in familial polypiosis coli. *Tohoku J Exp Med* 1978; **126**: 289-93.
15. Iida M, Nakamura T, Utsonomiya JJ. Osteomatous changes and tooth abnormalities found in the jaws of patients with adenomatosis coli. *Oral Surg* 1981; **52**: 2-11.
16. Jarvinen HJ, Peltokallio P, Landtman M *et al.* Gardners stigmas in familial adenomatosis coli. *Br J Surg* 1982; **69**: 718-21.
17. Bulow S, Sondergaard JO, Witt IN *et al.* Mandibular osteomas in familial polyposis coli. *Dis Colon Rectum* 1984; **27**: 105-8.
18. Wolf J, Jarvinen HJ, Hietanen J. Gardners dento-maxillary stigmas in patients with familial adenomatosis coli. *Br J Oral Maxillofac Surg* 1986; **24**: 410-6.
19. Carl W, Sullivan MA. Dental abnormalities and bone lesions in patients with familial adenomatous polyposis: report of two cases. *J Am Dent Assoc* 1989; **119**: 137-9.
20. Kubo K, Miyatani H, Takenoshita Y *et al.* Widespread radiopacity of jawbones in familial adenomatosis coli. *J Cranio Max Fac Surg* 1989; **17**: 350-3.
21. Jarvinen H, Nyberg M, Peltokallio P. Upper gastrointestinal tract polyps in familial adenomatosis coli. *Gut* 1983; **24**: 333-9.
22. Bulow S. Familial adenomatous polyposis. *Ann Med* 1989; **21**: 299-307.
23. Iida M, Yao T, Watanabe M *et al.* Fundic gland polyposis in patients without familial adenomatous polyposis: its incidence and clinical features. *Gastroenterology* 1984; **86**: 1437-42.
24. Cabot RC. Case 21061. *N Engl J Med* 1935; **212**: 263-7.
25. Arvanitis ML, Jagelman DG, Fazio VW *et al.* Mortality in patients with familial adenomatous polyposis. *Dis Colon Rectum* 1990; **33**: 639-42.
26. Spigelman AD, Williams TB, Talbot IC *et al.* Upper gastrointestinal cancer in a patients with familial adenomatous polyposis. *Lancet* 1989; **2**: 783-5.
27. Bulow S, Bjork J, Christensen IJ *et al.* Duodenal adenomatosis in familial adenomatous polyposis. *Gut* 2004; **93**: 381-6.
28. Groves CJ, Saunders BP, Spigelman AD *et al.* Duodenal cancer in familial adenomatous polyposis (FAP): results of 10 year prospective study. *Gut* 2002; **50**: 636-41.
29. Bjork J, Akerbrandt H, Iselius L *et al.* Periampullary adenomas and adenocarcinomas in familial adenomatous polyposis: cumulative risks and APC gene mutations. *Gastroenterology* 2001; **121**: 1127-35.
30. Ohsato K, Yao T, Watanabe H *et al.* Small intestinal involvement in familial polyposis as diagnosed by operative intestinal fiberoscopy: report of four cases. *Dis Colon Rectum* 1977; **20**: 414-20.
31. Iida M, Itoh M, Matsui T *et al.* Ileal adenomas in postcolectomy patients with familial adenomatosis coli/Gardners syndrome. Incidence and endoscopic appearance. *Dis Colon Rectum* 1989; **32**: 1034-8.
32. Rodriguez-Bigas MA, Penetrante RB, Herrera L *et al.* Intraoperative small bowel enteroscopy in familial adenomatous and familial juvenile polyposis. *Gastrointest Endoscopy* 1995; **42**: 560-4.
33. Beveridge IG, Swain DJ, Groves CJ *et al.* Large villous adenomas arising in ileal pouches in familial adenomatous polyposis: report of two cases. *Dis Colon Rectum* 2004; **47**: 123-6.
34. Thomson-Fawcett MW, Marcus VA, Redston M *et al.* Adenomatous polyps develop commonly in the ileal pouch of patients with familial adenomatous polyposis. *Dis Colon Rectum* 2001; **44**: 347-53.
35. Van Duijvendijk P, Vasen HF, Bertario L *et al.* Cumulative risk of developing polyps or malignancy at the ileal pouch-anal anastomosis in patients with familial adenomatous polyposis. *J Gastrointest Surg* 1999; **3**: 325-30.
36. Reitamo JJ, Scheinin TM, Hayry P. The desmoid syndrome: new aspects in the cause, pathogenesis and treatment of the desmoid tumour. *Am J Surg* 1986; **151**: 230-7.
37. Gurbuz AK, Giardello FM, Petersen GM *et al.* Desmoid tumours in familial adenomatous polyposis. *Gut* 1994; **35**: 377-81.
38. Clark SK, Philips RK. Desmoids in familial adenomatous polyposis. *Br J Surg* 1996; **83**: 1494-504.
39. Church JM, McGannon E, Ozuner G. The clinical course of intra-abdominal desmoid tumours in patients with familial adenomatous polyposis. *Colorectal Disease* 1999; **1**: 168-73.
40. Soravia C, Berk T, McLeod RS *et al.* Desmoid disease in patients with familial adenomatous polyposis. *Dis Colon Rectum* 2000; **43**: 363-9.
41. Heiskanen I, Jarvinen HJ. Occurrence of desmoid tumours in familial adenomatous polyposis and results of treatment. *Int J Colorectal Dis* 1996; **11**: 157-62.
42. Vasen HFA, Bulow S, The Leeds Castle Polyposis Group. Guidelines for the surveillance and treatment of familial adenomatous polyposis (FAP): a world wide survey among 41 registries. *Colorectal Disease* 1999; **1**: 214-21.
43. Leppard BJ. Epidermoid cysts and polyposis coli. *Proc Roy Soc Med* 1974; **67**: 1036-7.